Endoscopic Ultrasound Guided Fine Needle Aspiration/Biopsy

Saturday 21st October 2017
Cytology Society of the South West and South Wales

Lachlan Ayres
Consultant Gastroenterologist
Poole Hospital NHS Foundation Trust

Outline

- Endoscopic ultrasound
- Equipment
- Cases
- Poole experience

EUS Equipment

Linear

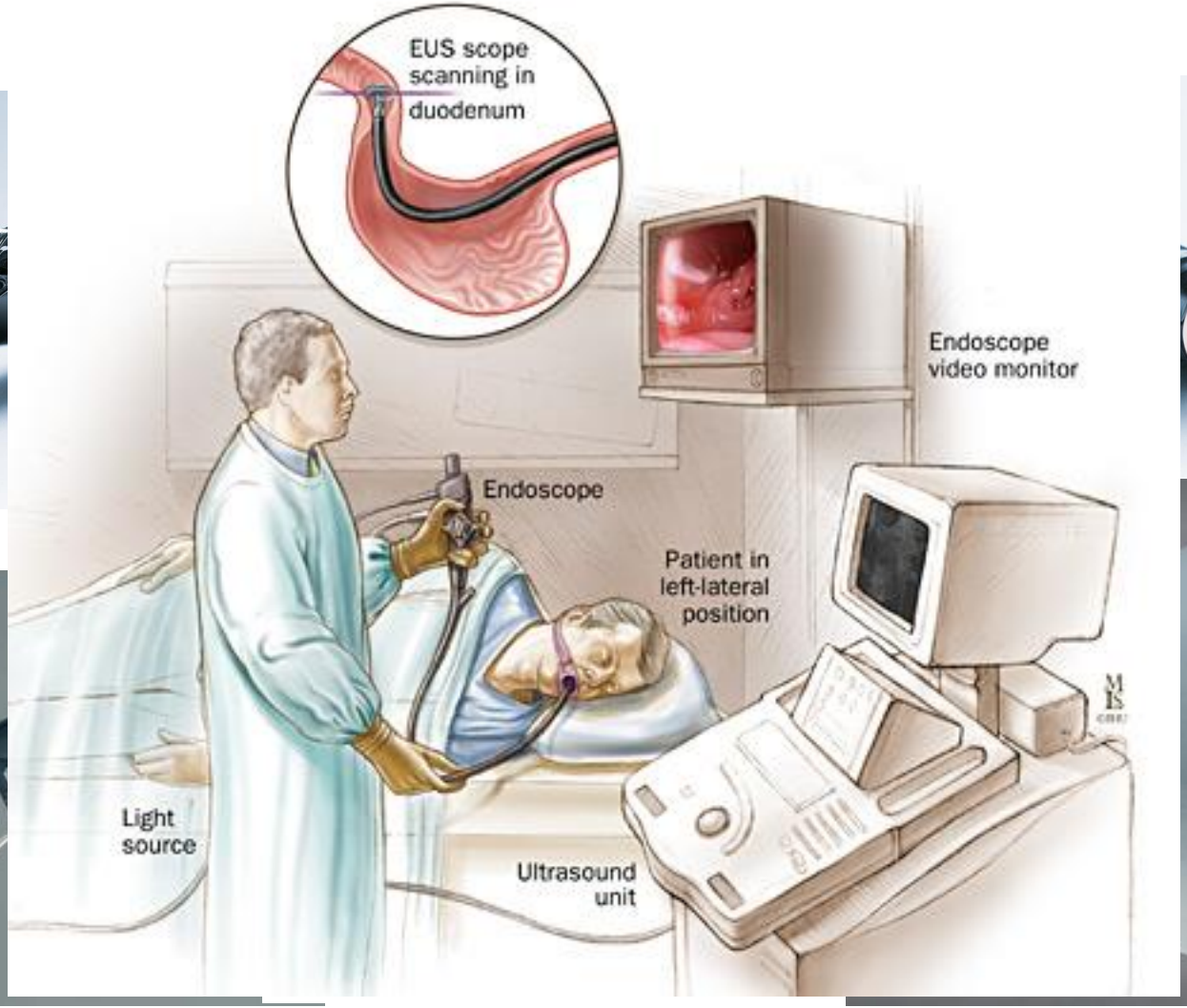

EUS

Linear

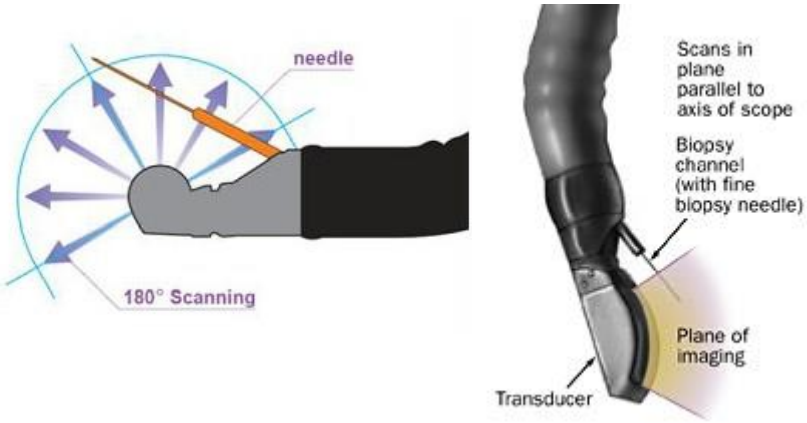

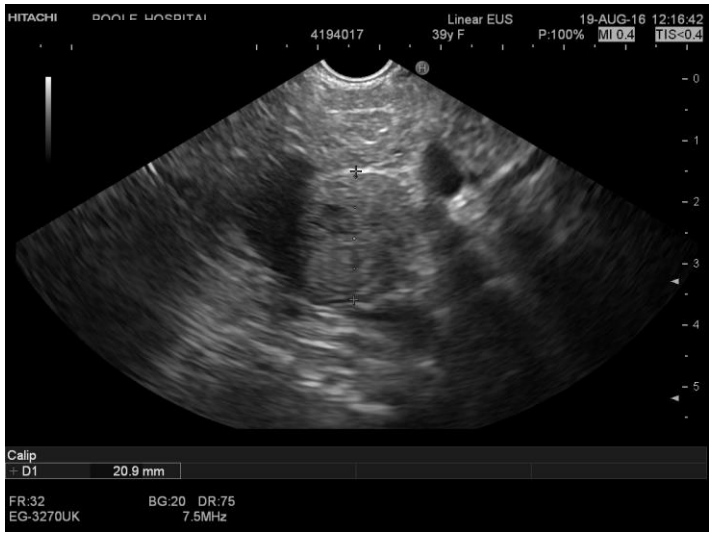

Radial

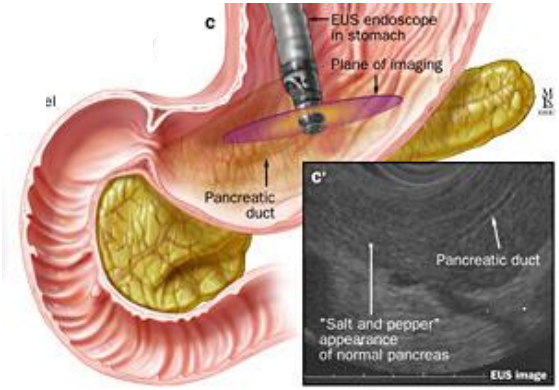

Case 1

- 71 yr old lady
- Episodic abdo pain
- Normal liver function tests
- US: 14mm pancreatic cyst with internal echoes. Gallstones. Otherwise normal pancreas.

- Conclusion ?pseudocyst

- PMH:
  - Crohn's colitis
  - Renal cell ca (R nephrectomy 2000)
  - Breast ca (L mastectomy 2006)

Case 1 - US

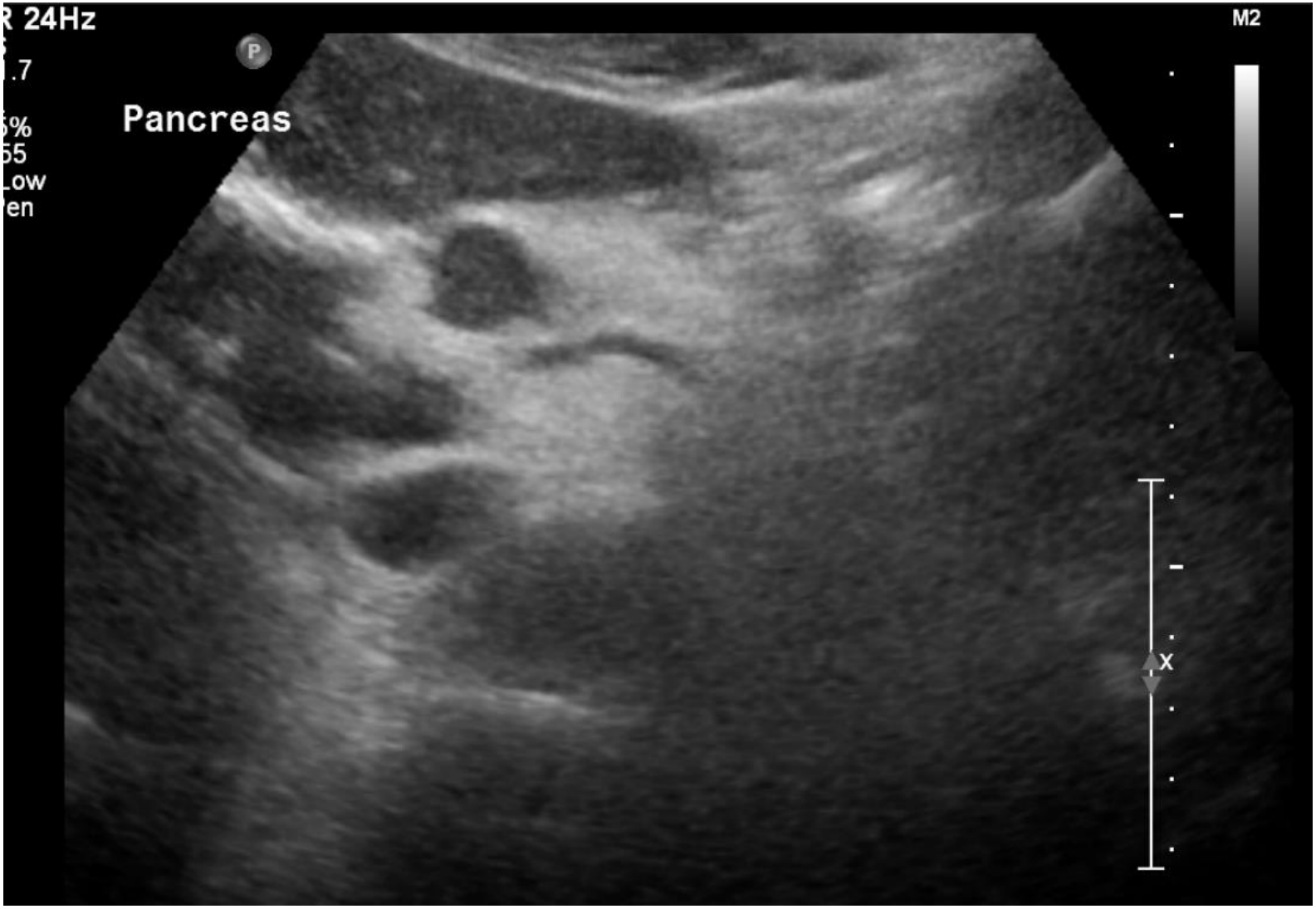

Case 1 - MRCP

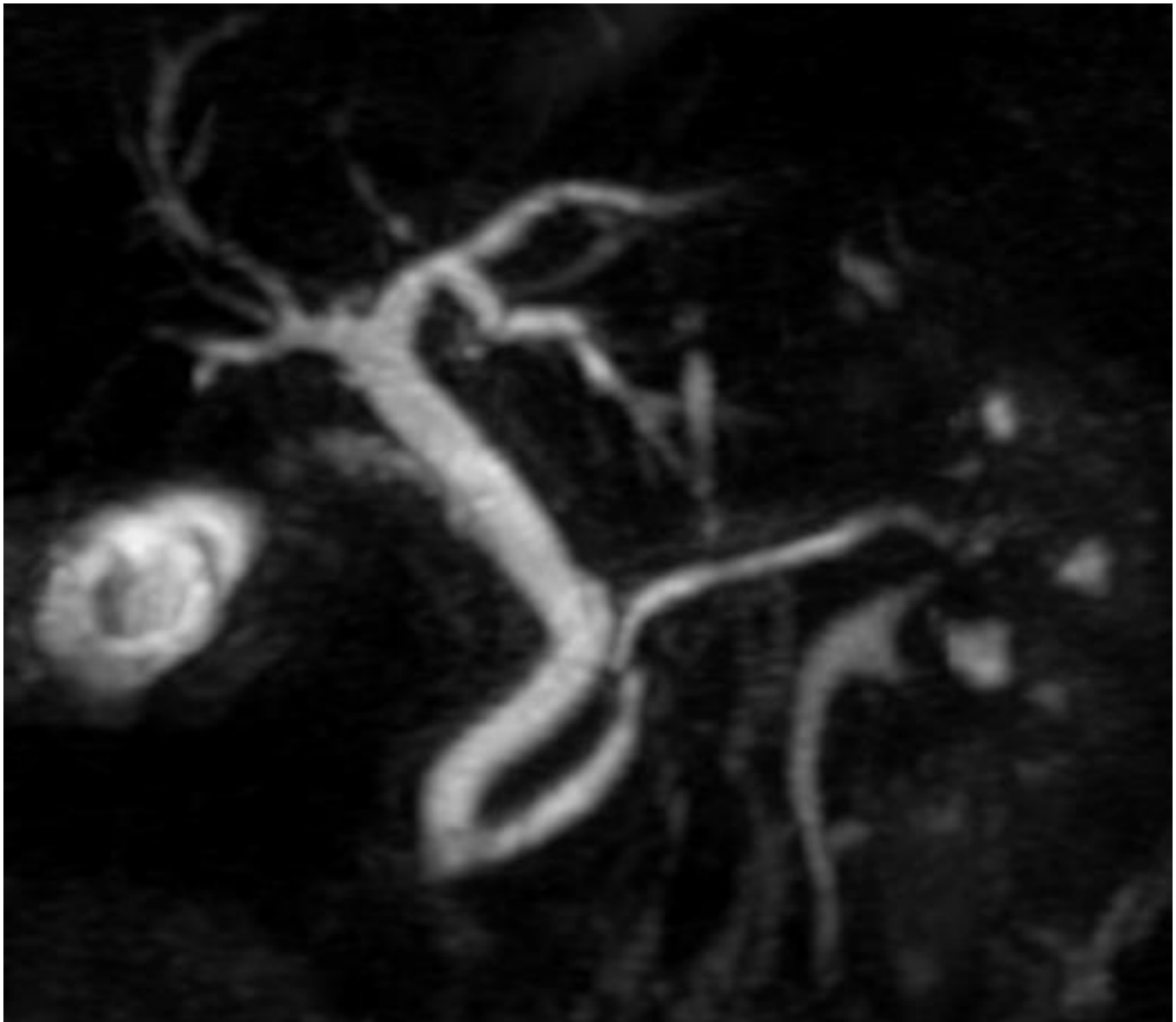

Case 1 - MR

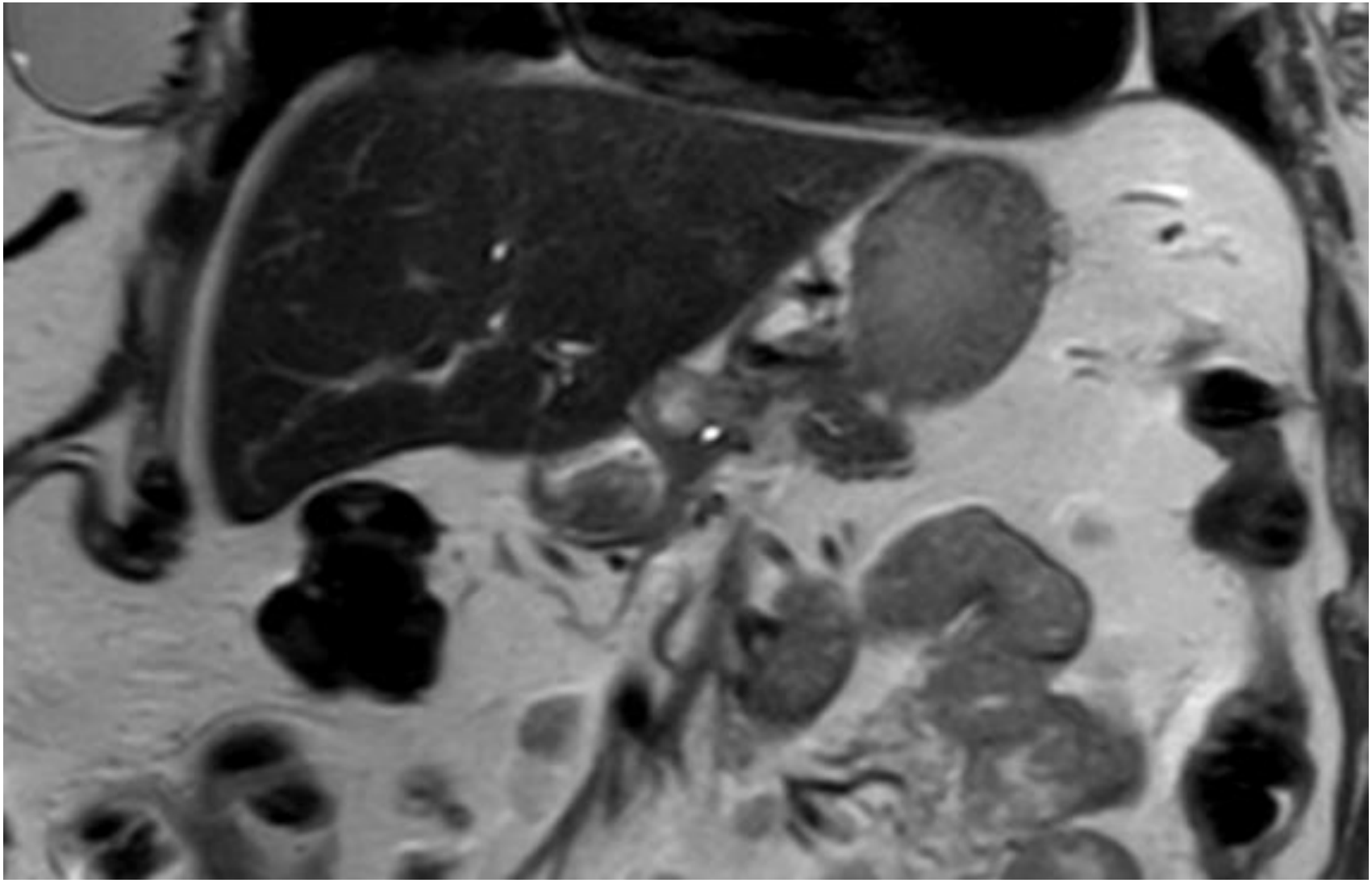





Case 1 - EUS

Stomach

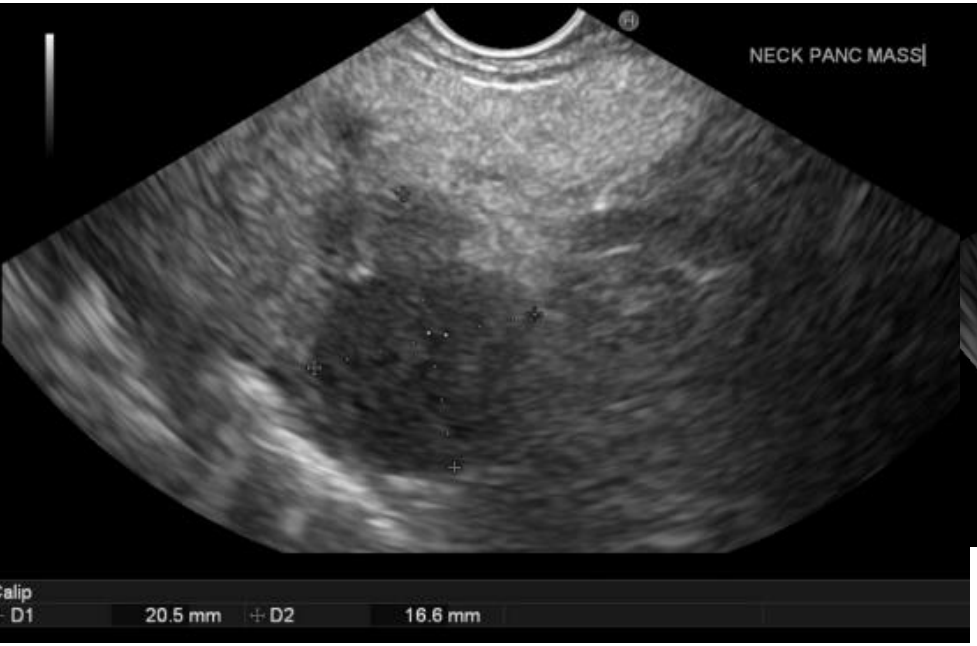

Duodenum

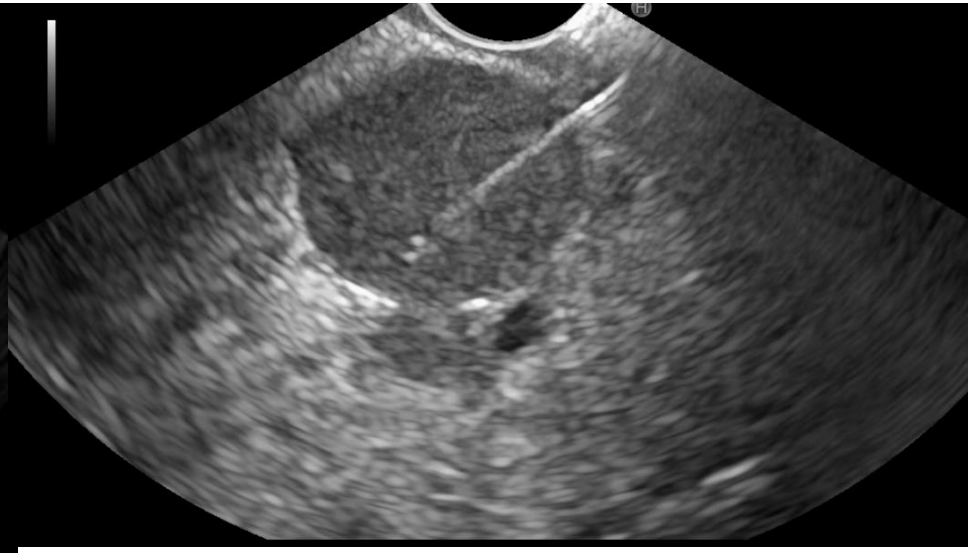

Differential

- Pancreatic cancer
- Neuroendocrine tumour
- Solitary met (RCC, breast less likely)

Case 1 Pancreatic Mass Core Rapid MGG

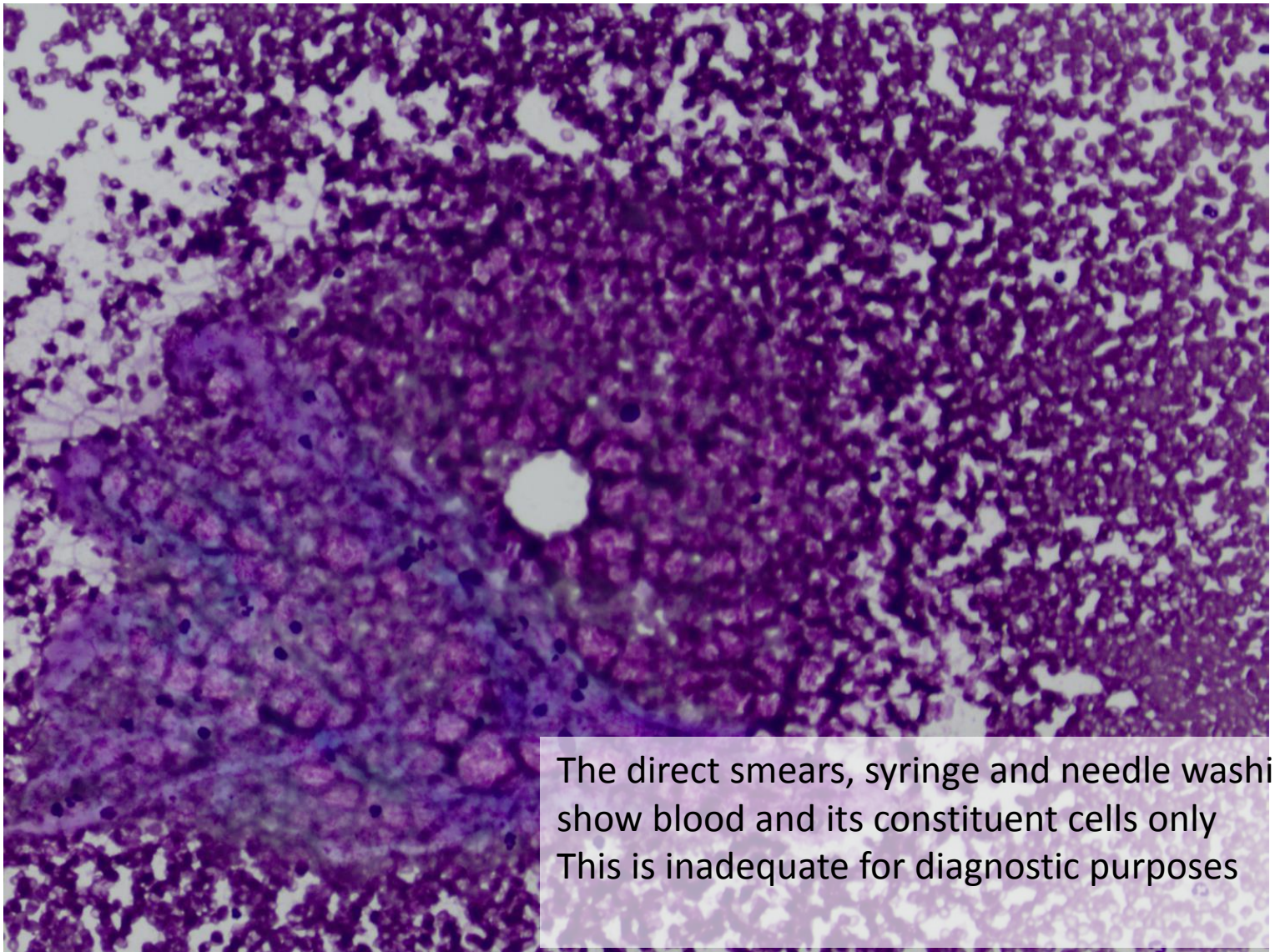

The direct smears, syringe and needle washings all show blood and its constituent cells only
This is inadequate for diagnostic purposes

Case 1 - Pancreatic Mass Core H&E

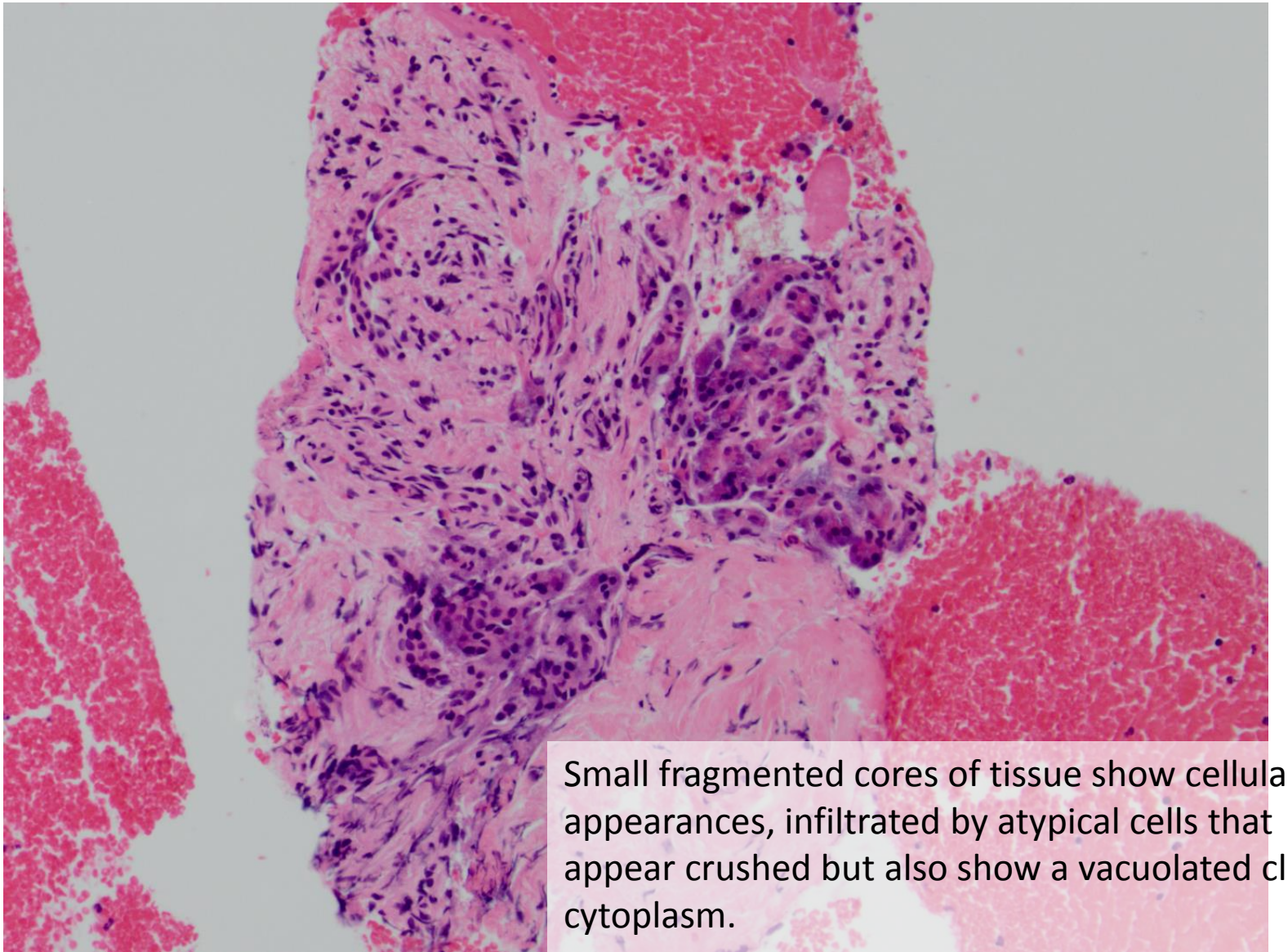

Small fragmented cores of tissue show cellular appearances, infiltrated by atypical cells that appear crushed but also show a vacuolated clear cytoplasm.

Case 1- Pancreatic Mass Core CD10

Core Vimentin

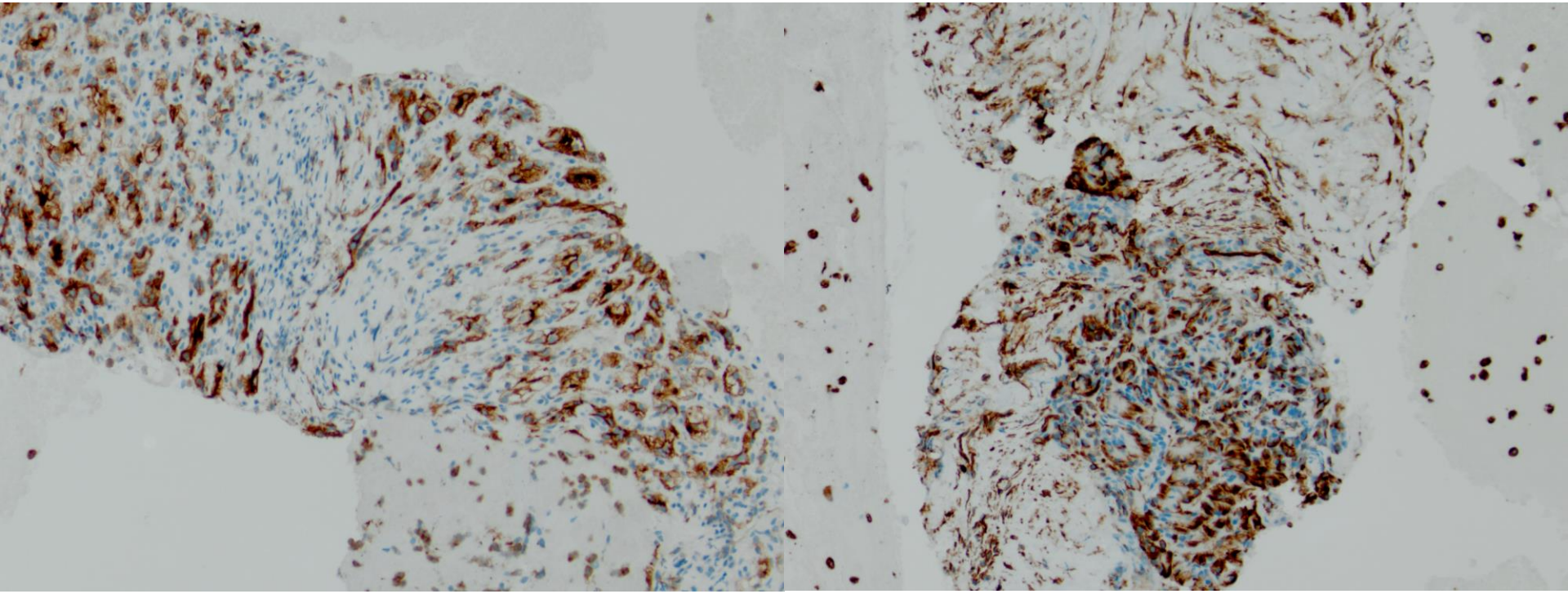

These cells stain positively with CD10 and Vimentin
CK7 is only focally positive.
Racemase (AMACR) immunohistochemistry also shows focal cytoplasmic positivity
A small focus of pancreatic neuroendocrine cells is also seen in the background

Case 1 - Pancreatic Mass Core AMACR

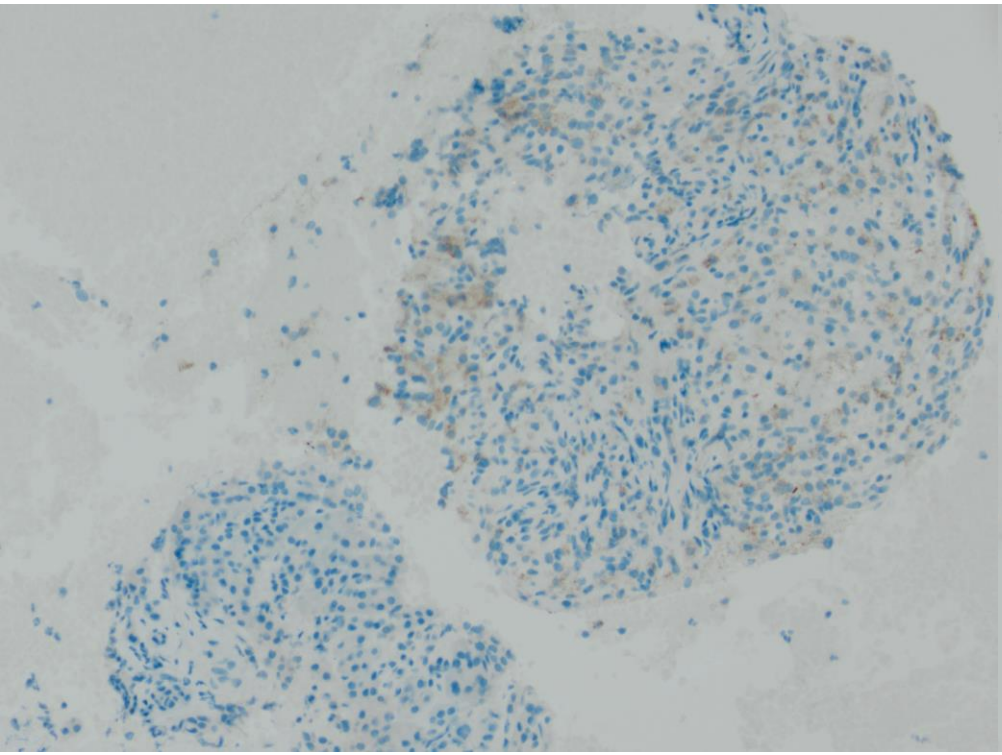

Case 1 - Pancreatic Mass Core CK7

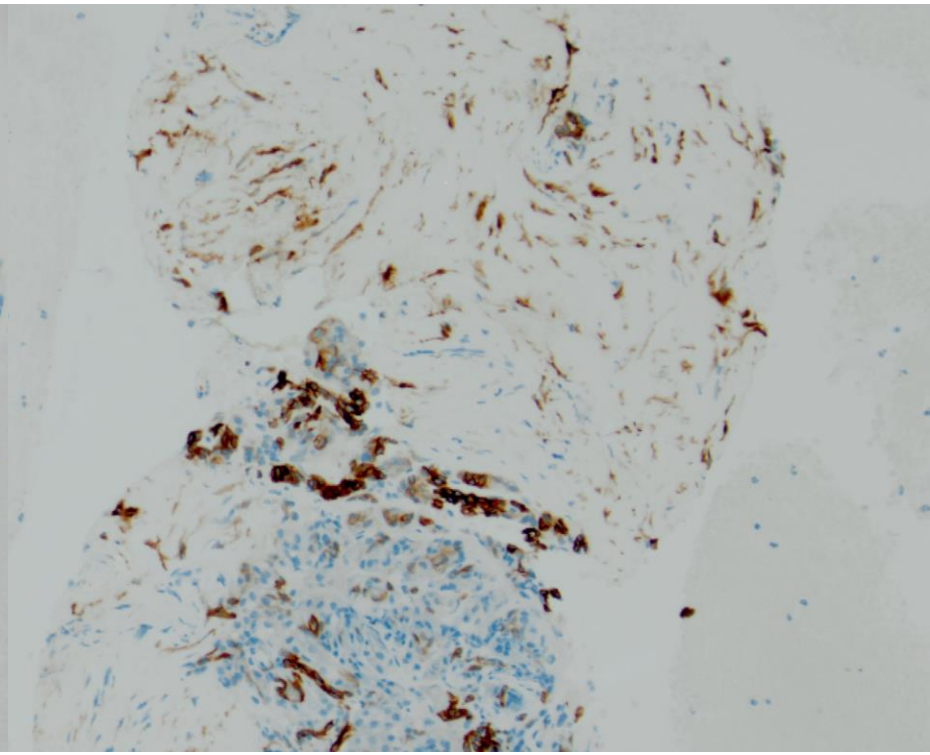

Immunoprofile

- Overall, in the context of the history of renal cell carcinoma, highly likely to represent metastatic RCC.
- Further RCC specific renal markers (Pax2 and RCC) were requested
- Further immunohistochemical staining with the RCC antibody show positive cytoplasmic staining and offers further support to the diagnosis of metastatic RCC.

EUS applications

- Biliary stones/microlithiasis
- Undifferentiated mass lesions
- Pancreatic lesions
  - Cystic
  - Solid
- Subepithelial lesions
- Cancer staging

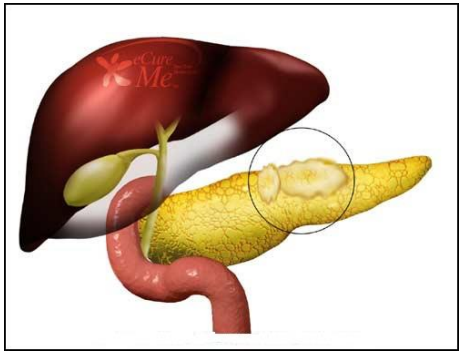

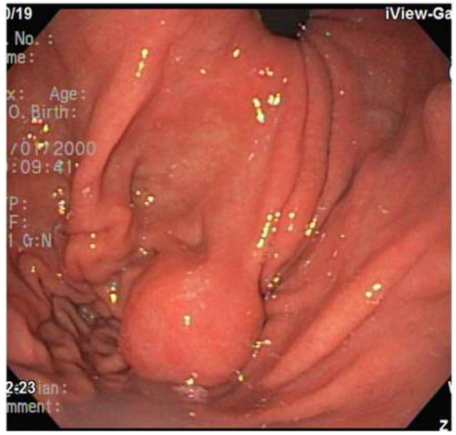

EUS at Poole

- 15 months
- Evolving service
- ROSE = rapid onsite evaluation – team of 5
- So far…
  - 150 cases
  - 70 FNA/B
  - High doses of sedation (GA rarely required)
  - Sensitivity for solid lesions ~80-85% overall but increasing
  - Complications
    - 1 abdominal pain
    - 1 pseudocyst

Fine Needle A or B?

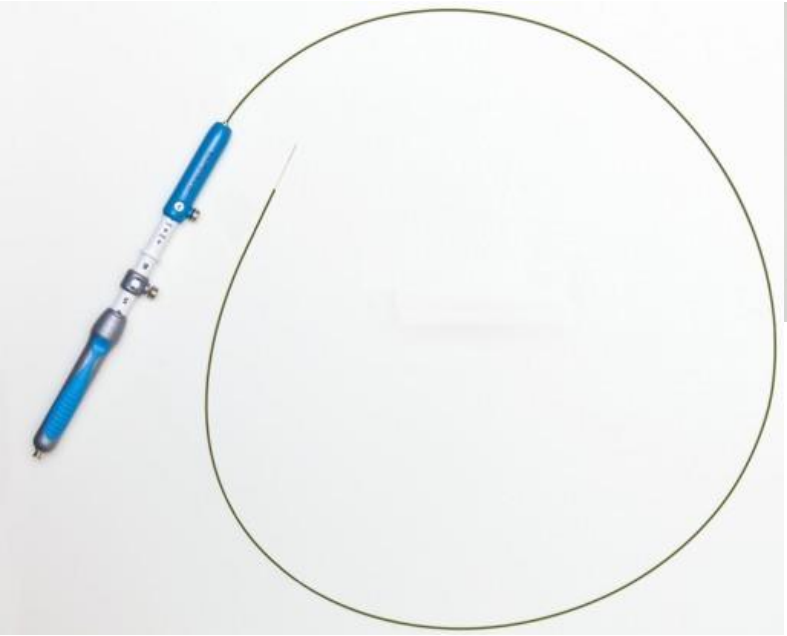

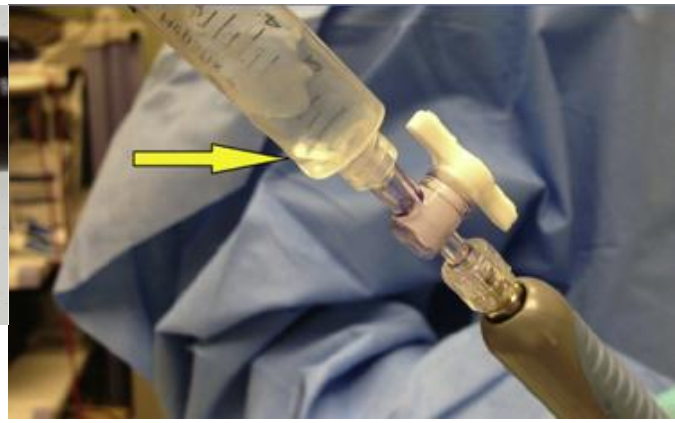

FNA

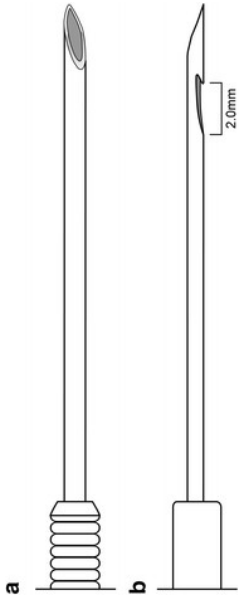

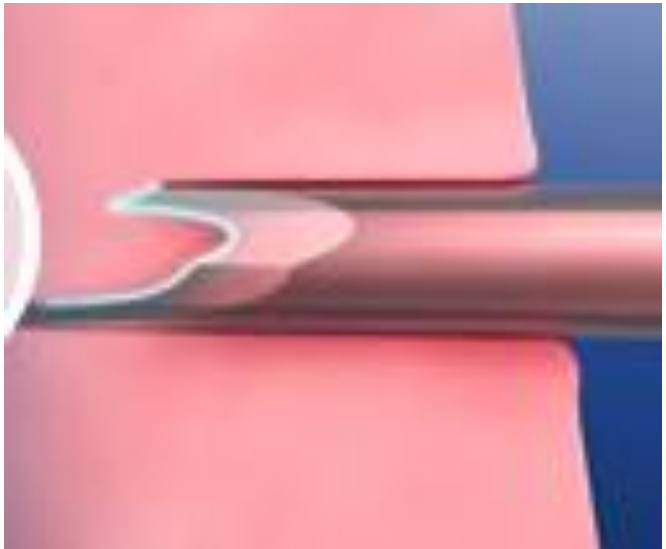

FNB

Poole EUS experience

- FNA needle
- Slides
- Washings
- Cell block

- FNB core needle
- Slides
- Washings
- “Worms”

Case 2

- 70 yr old iron deficiency anaemia

- Gastroscopy
  - Proximal stomach

Case 2 - Histology

- Gastric polyps –
  - Tumour cell aggregates. Inconspicuous mitotic activity. Reactivity to synaptophysin and CD56 (NET markers). Proliferation index with Ki 67<2%.
  - Grade 1 gastric NET
- Chromogranin A high
- PPI stopped – gastrin high
- GI bleed

Gastric NETs

	Associations	
• Type I (80%)	– Atrophic gastritis	High gastrin
• Type II (5%)	– Zollinger Ellis Syndrome /(MEN 1)	High gastrin
• Type III (15%)	– (rare)	Normal gastrin

TYPE II

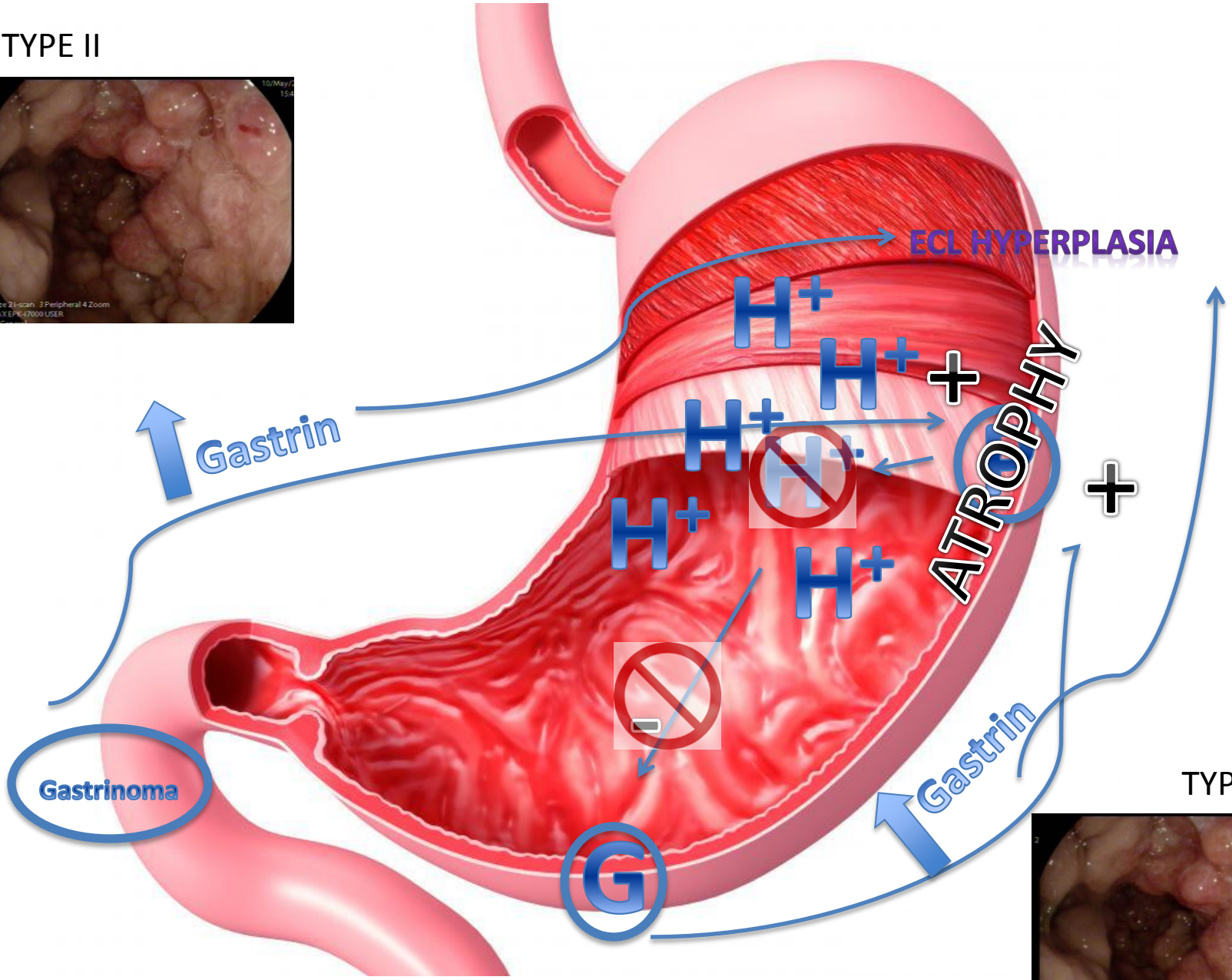

TYPE I

Case 2 - CT

Case 2 - MRI

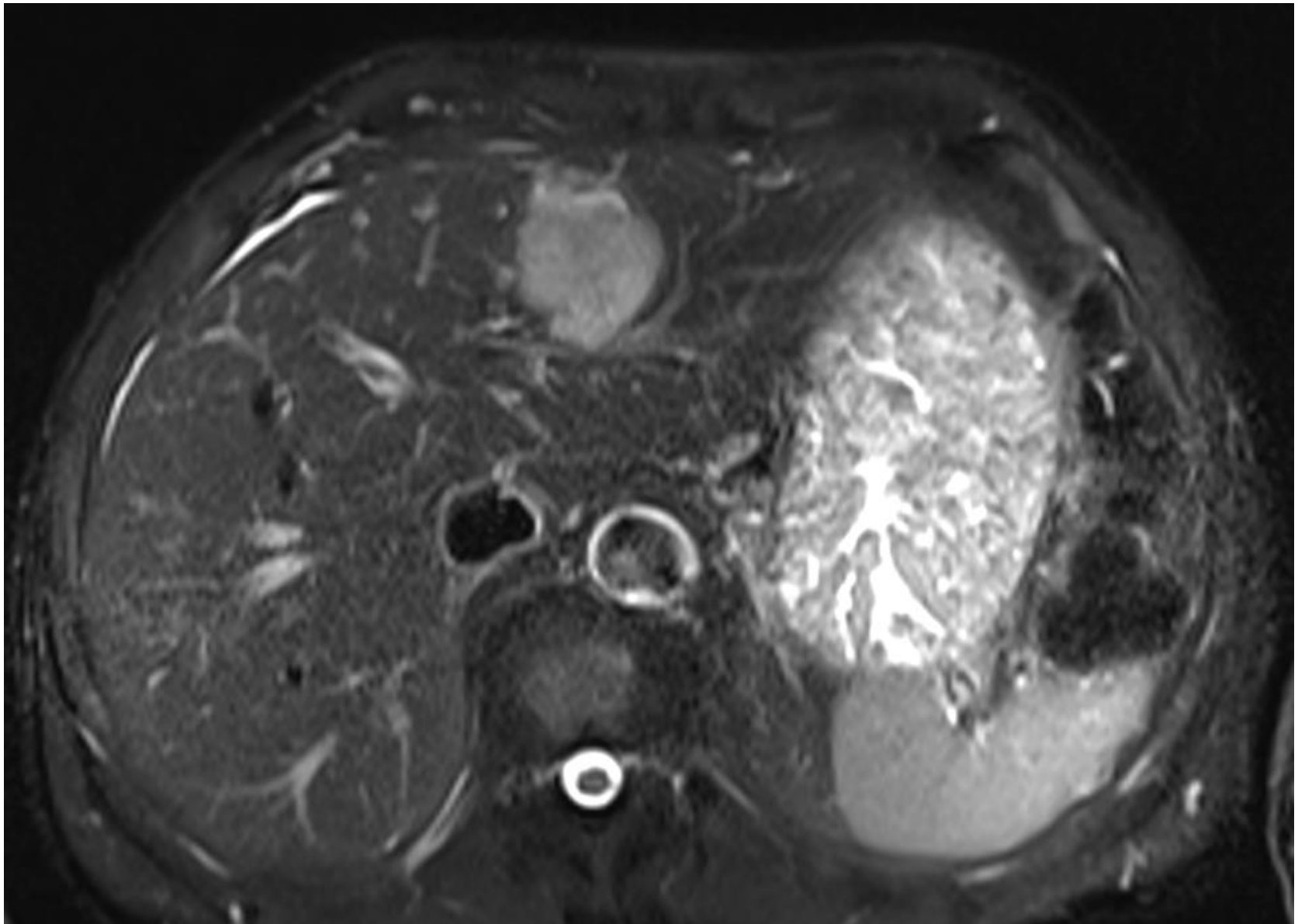

Case 2 - PET tektrotyd

99mTc-(EDDA)-HYNIC-TOC

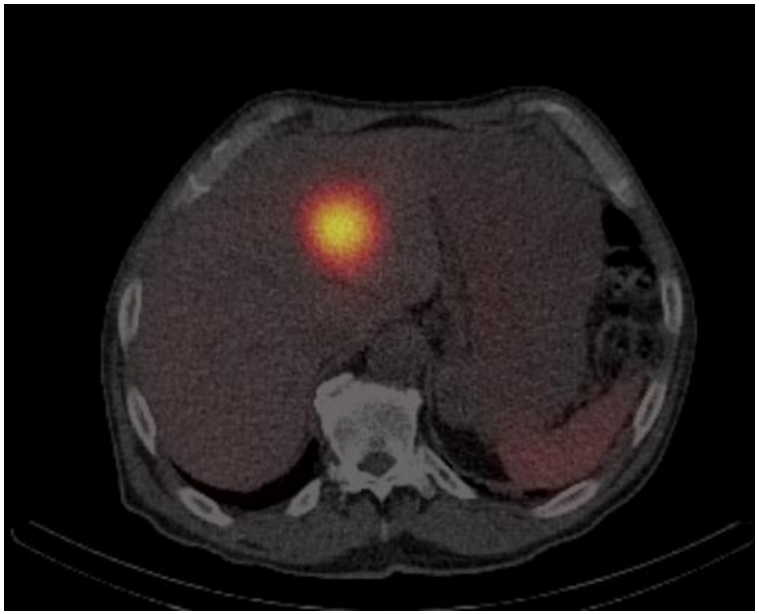

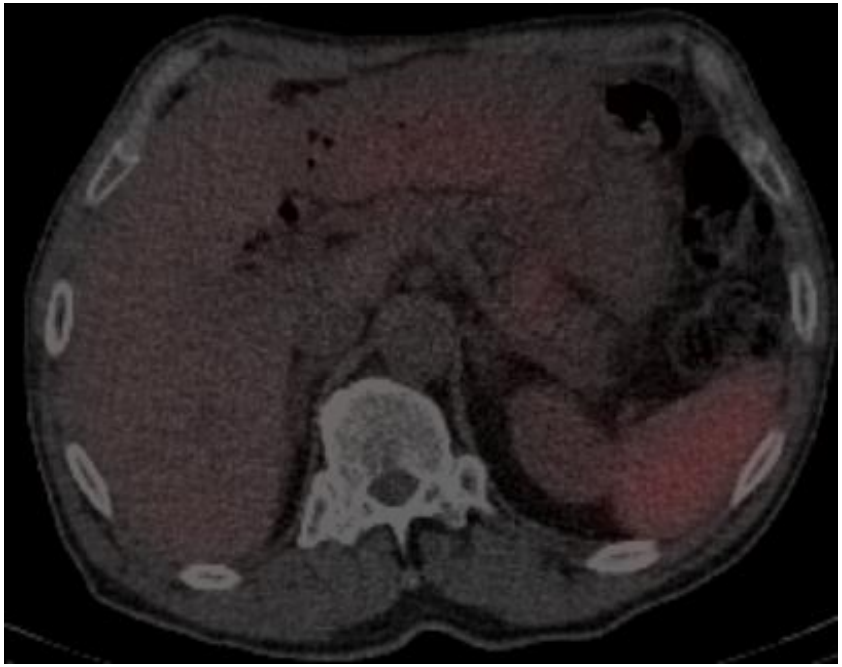

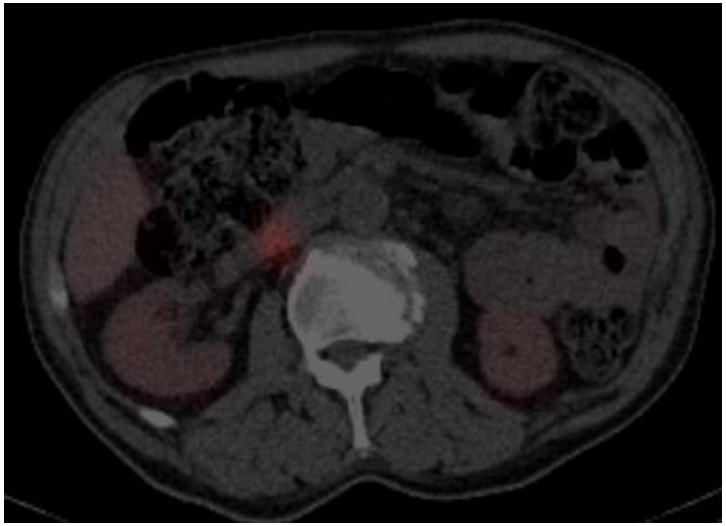

EUS





Histology

- TOP mass: NET.
- Caval LN: NET.

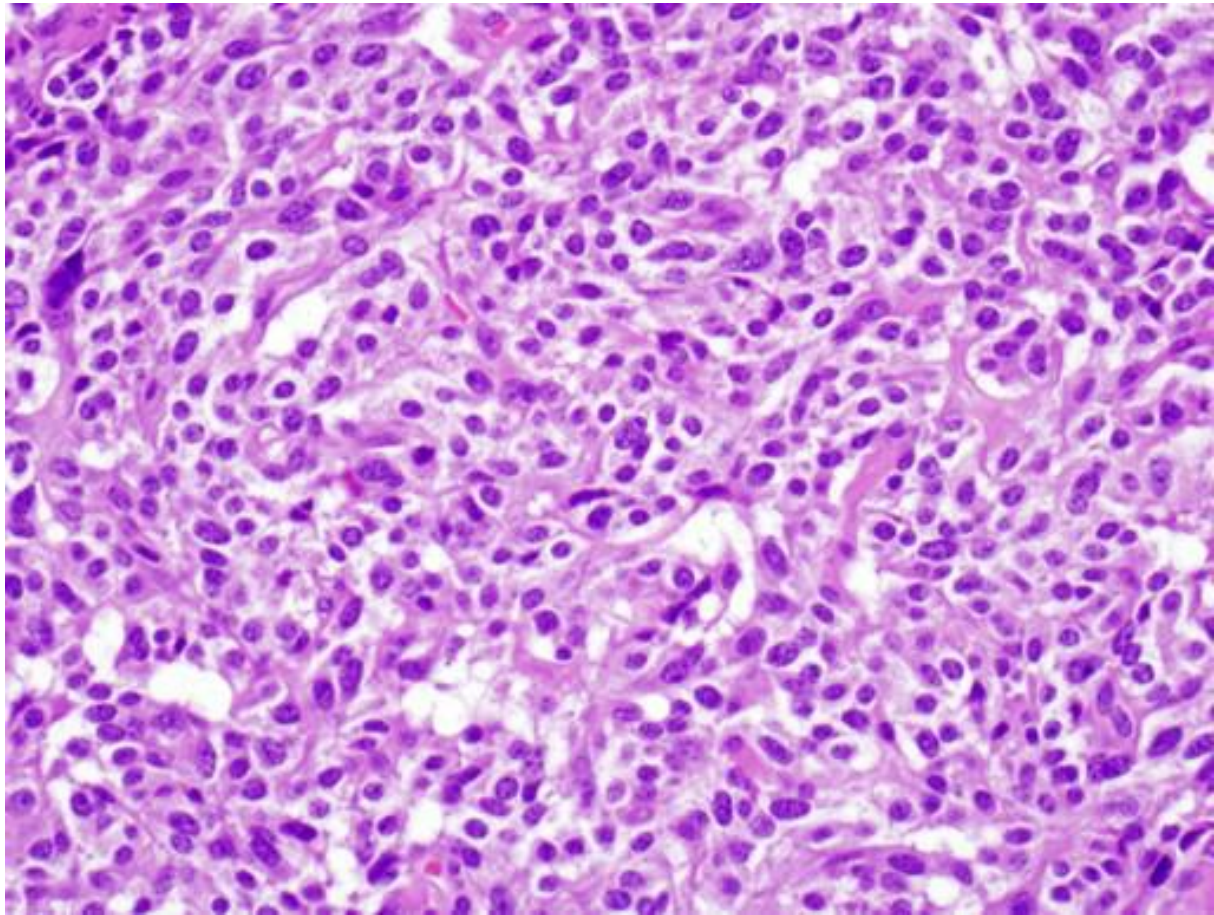

Case 2 - Summary

- Gastric NET type II / Zollinger Ellison Syndrome
- Functioning pNET with LN and liver mets

- Other considerations…
- MEN 1 (20-30% of gastrinomas)
  - 1) Primary hyperparathyroidism
  - 2) Pituitary: MRI brain N

- Outcome: Lanreotide. Debulking surge

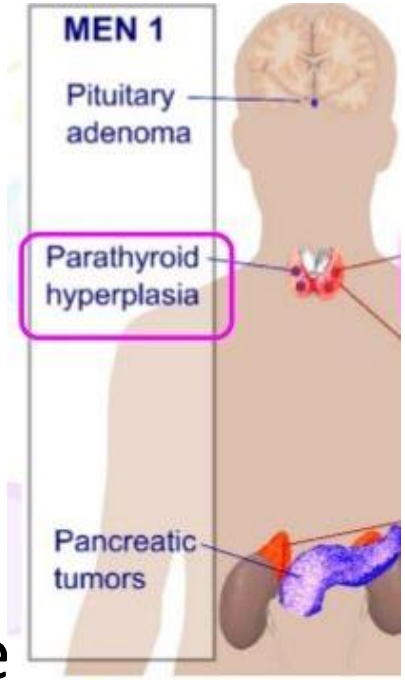

Learning points

- Pancreatic NET: hypervascular, well-circumscribed, round
- NET: can be diagnosed biochemically ChA/urine 5HIAA
- EUS FNA/B can provide tissue diagnosis of primary, confirm LN mets, improves sensitivity for multiple pNETs

Case 3

- 50 yr old lady
- Spinal cord compression
- CT: multiple lesions, disseminated malignancy, possibly lung primary
- Oncology opinion:
  - Radiotherapy for cord compression
  - Tissue to guide further treatment

Case 3

- Lung lesion – inaccessible

Case 3

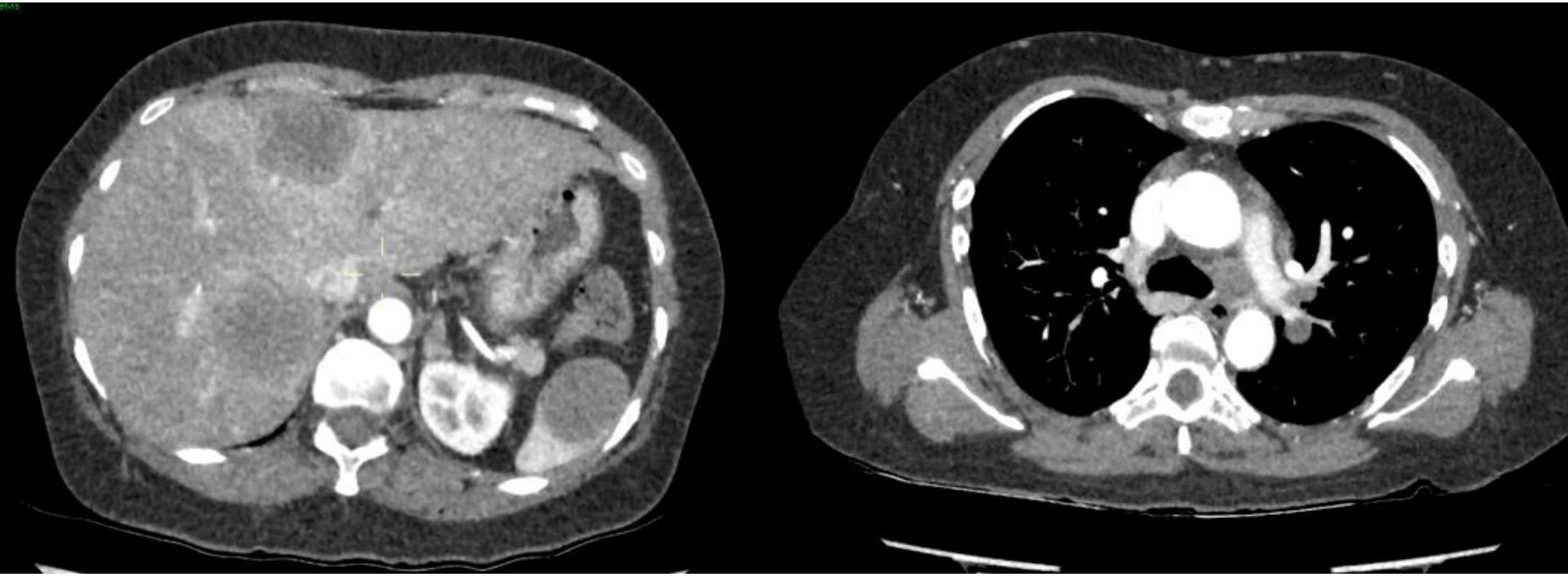

Liver mets – US guided biopsy necrotic material only

Case 3



Case 3

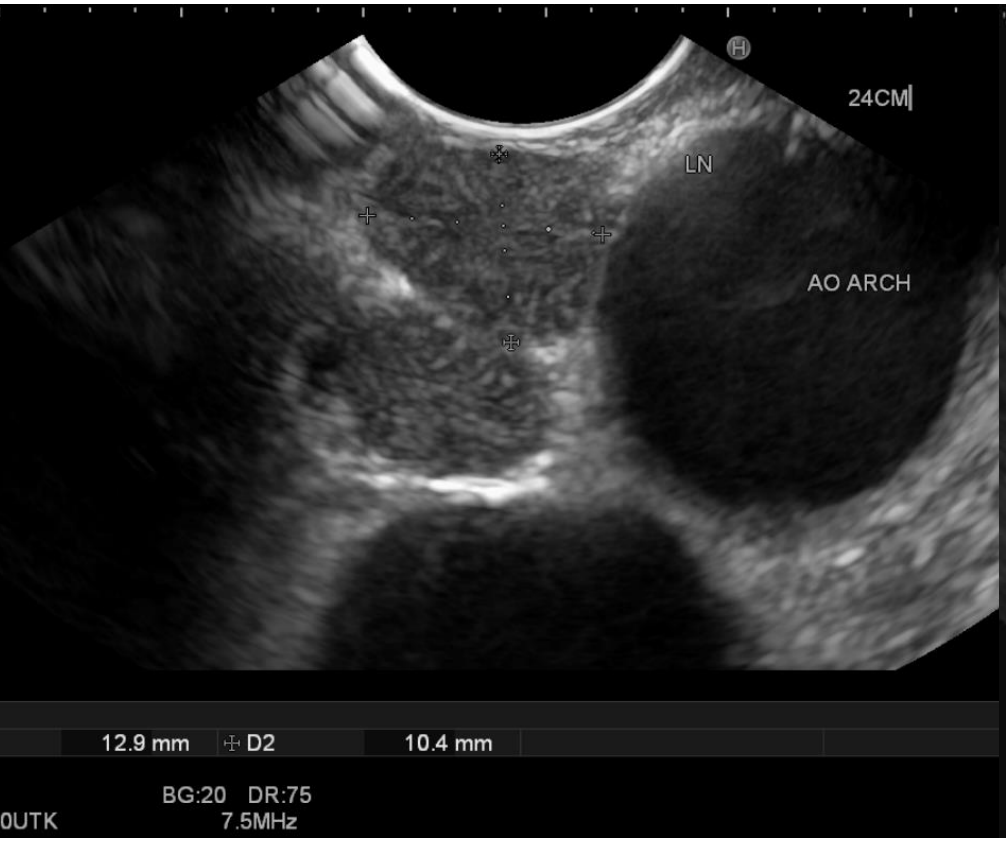

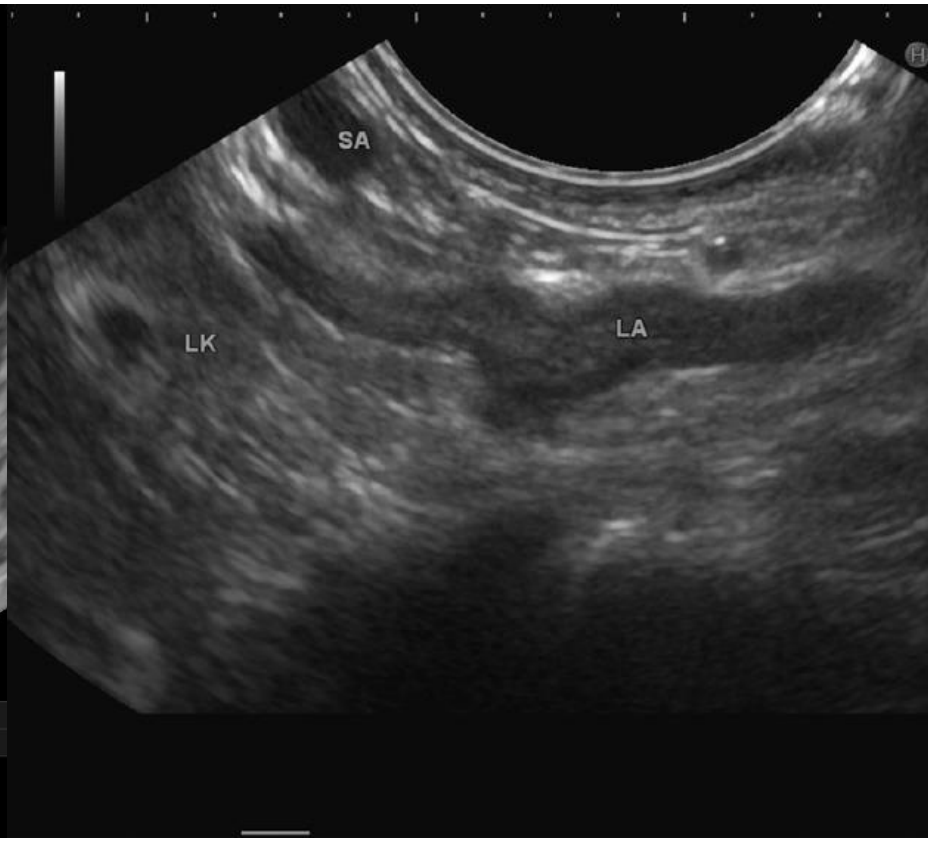

Case 3 - Mediastinal LN Core LBC

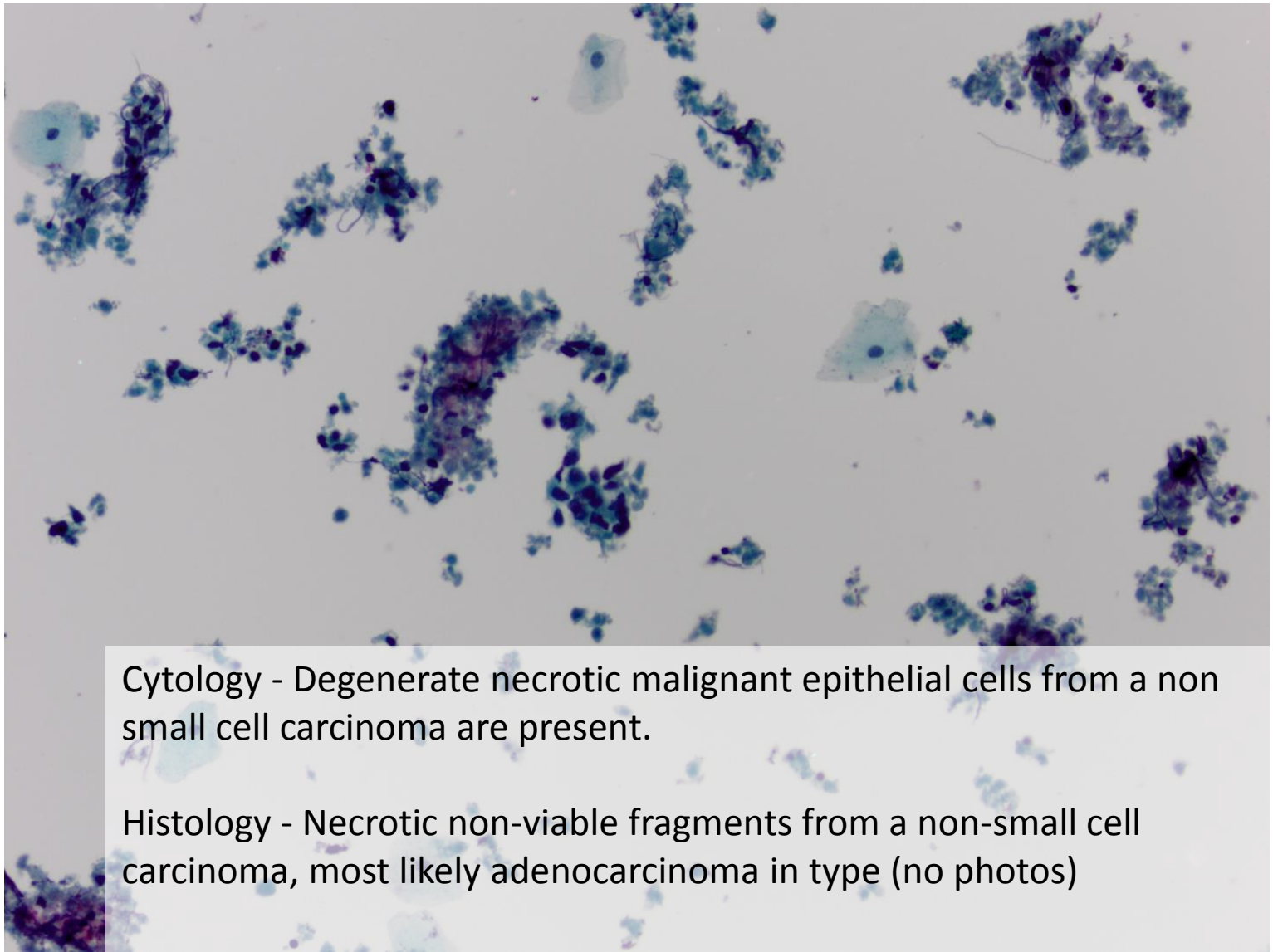

Cytology - Degenerate necrotic malignant epithelial cells from a non small cell carcinoma are present.

Histology - Necrotic non-viable fragments from a non-small cell carcinoma, most likely adenocarcinoma in type (no photos)

Case 3 - Mediastinal LN Core LBC 2

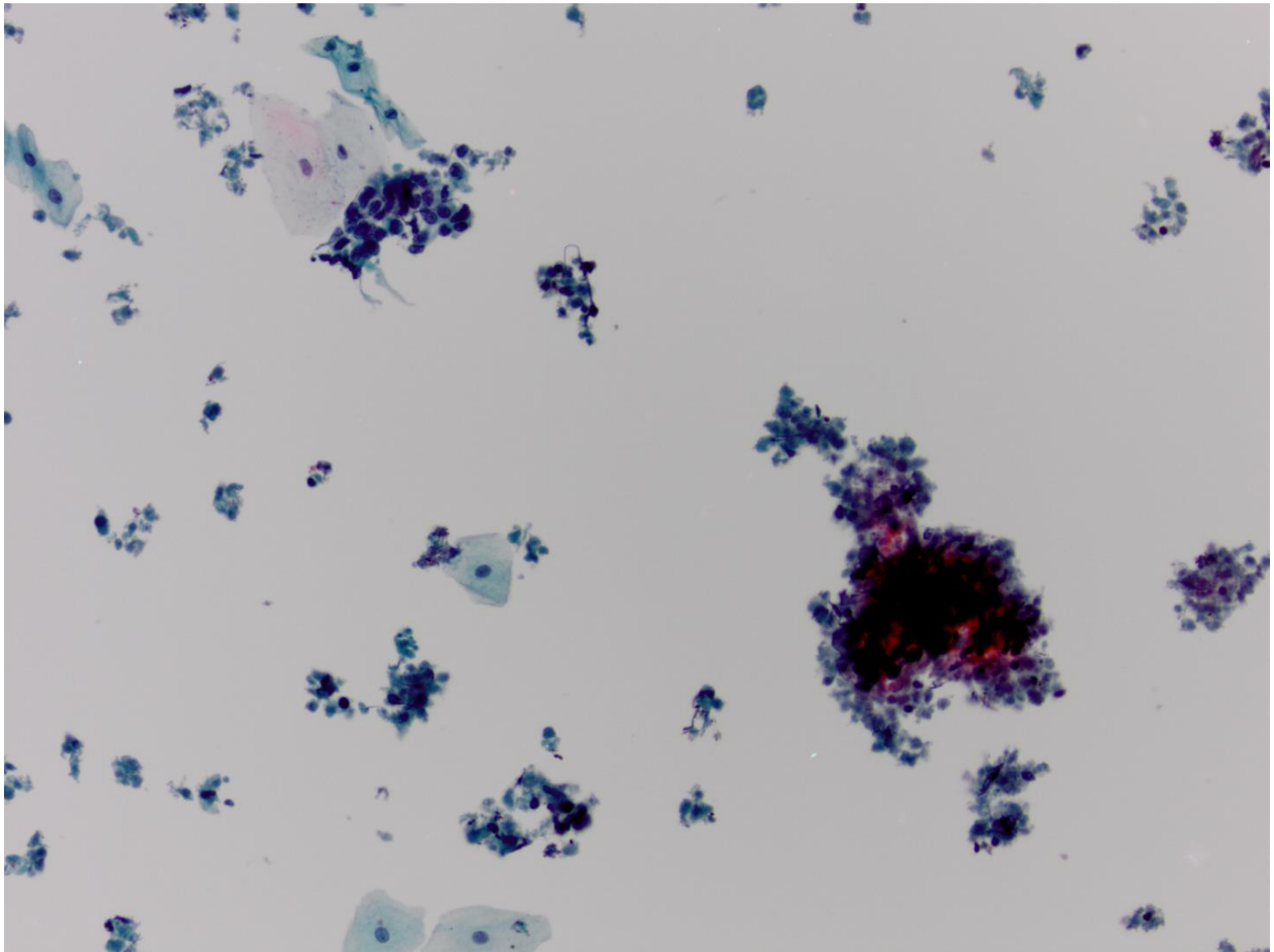

Case 3 - Mediastinal LN Core Rapid MGG

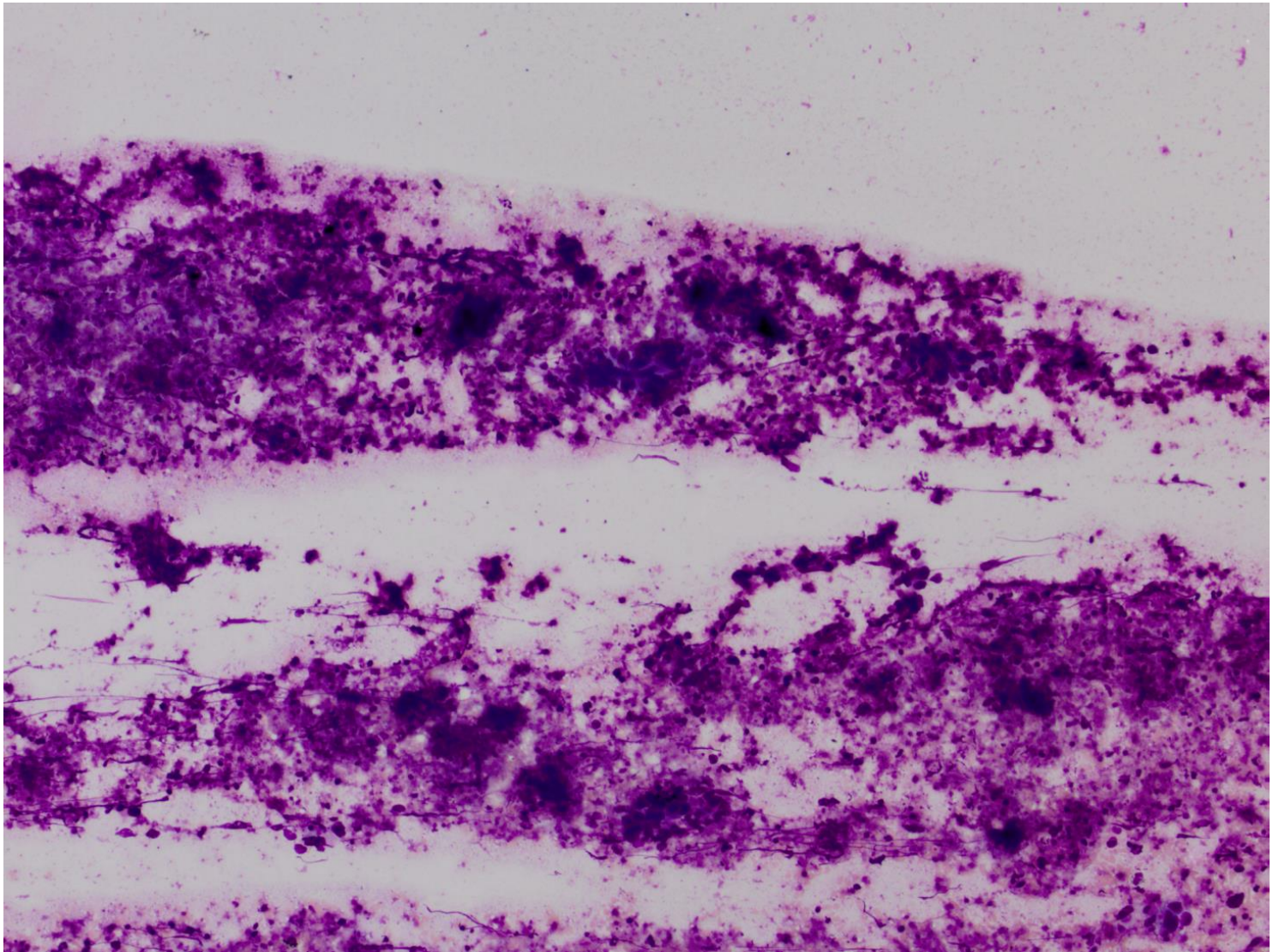

Case 3 - Mediastinal LN Core Rapid MGG 2

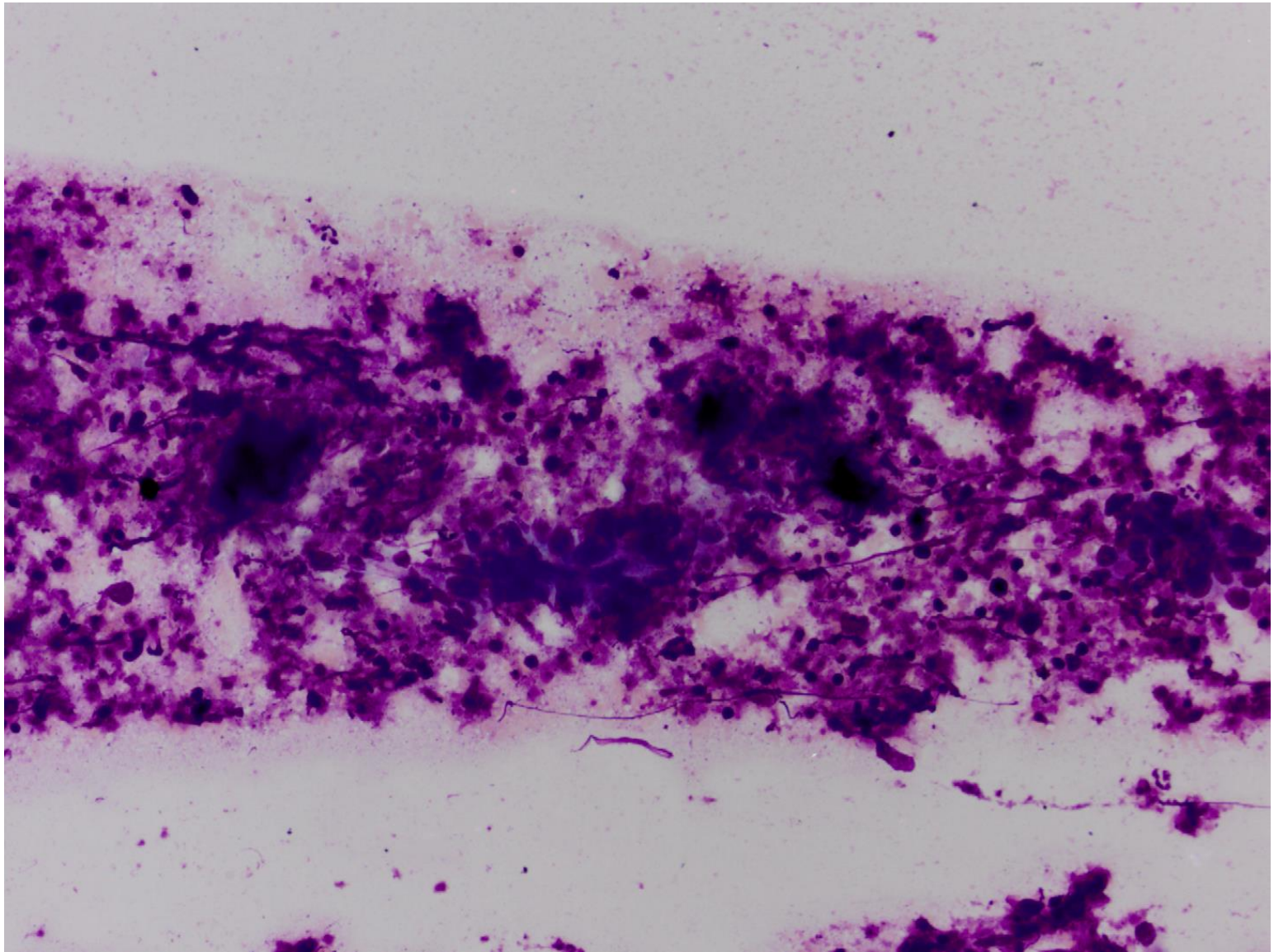

Case 3 - Mediastinal LN Core Rapid MGG 3

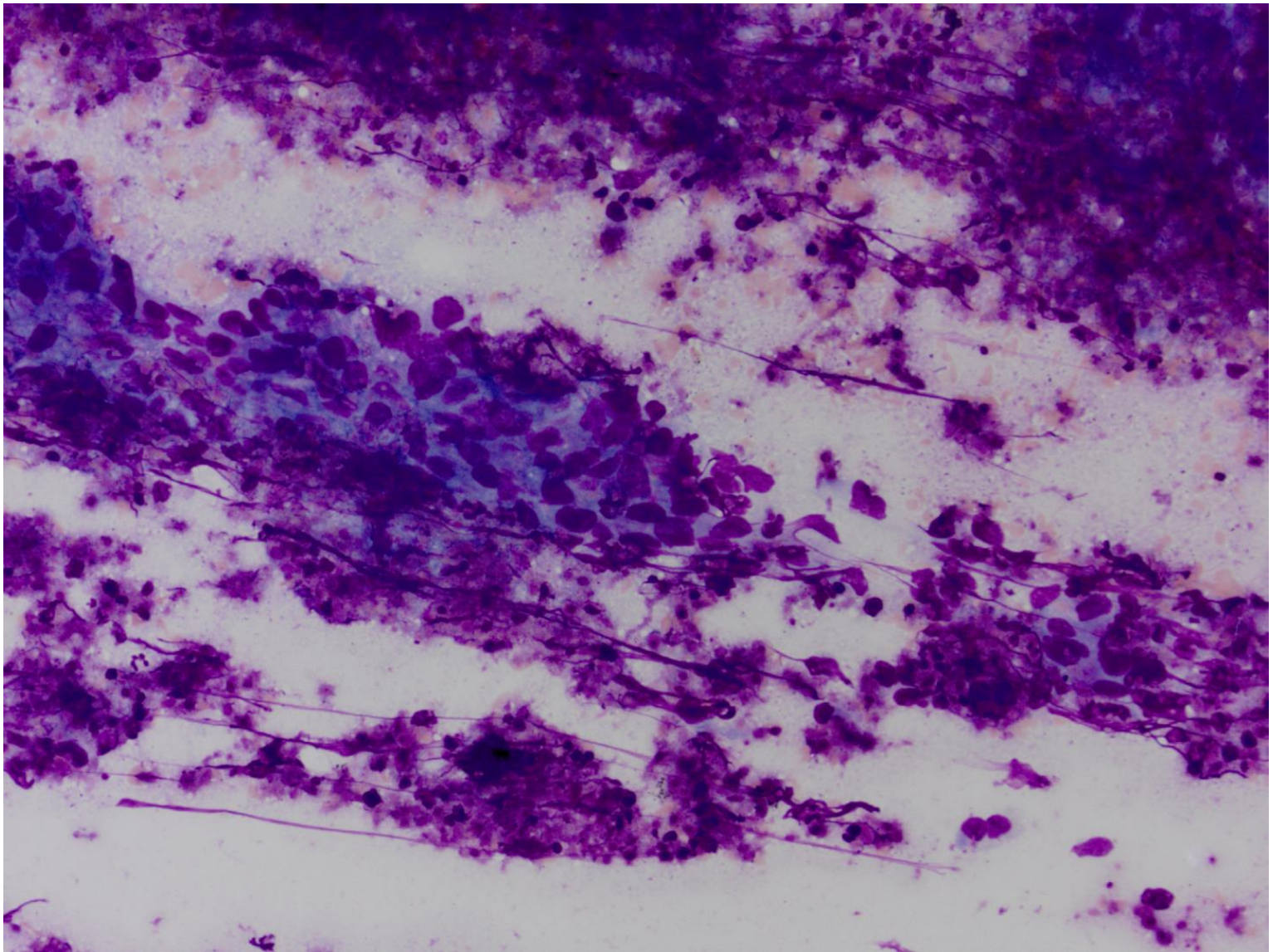

Case 3 - Adrenal Mass Core LBC

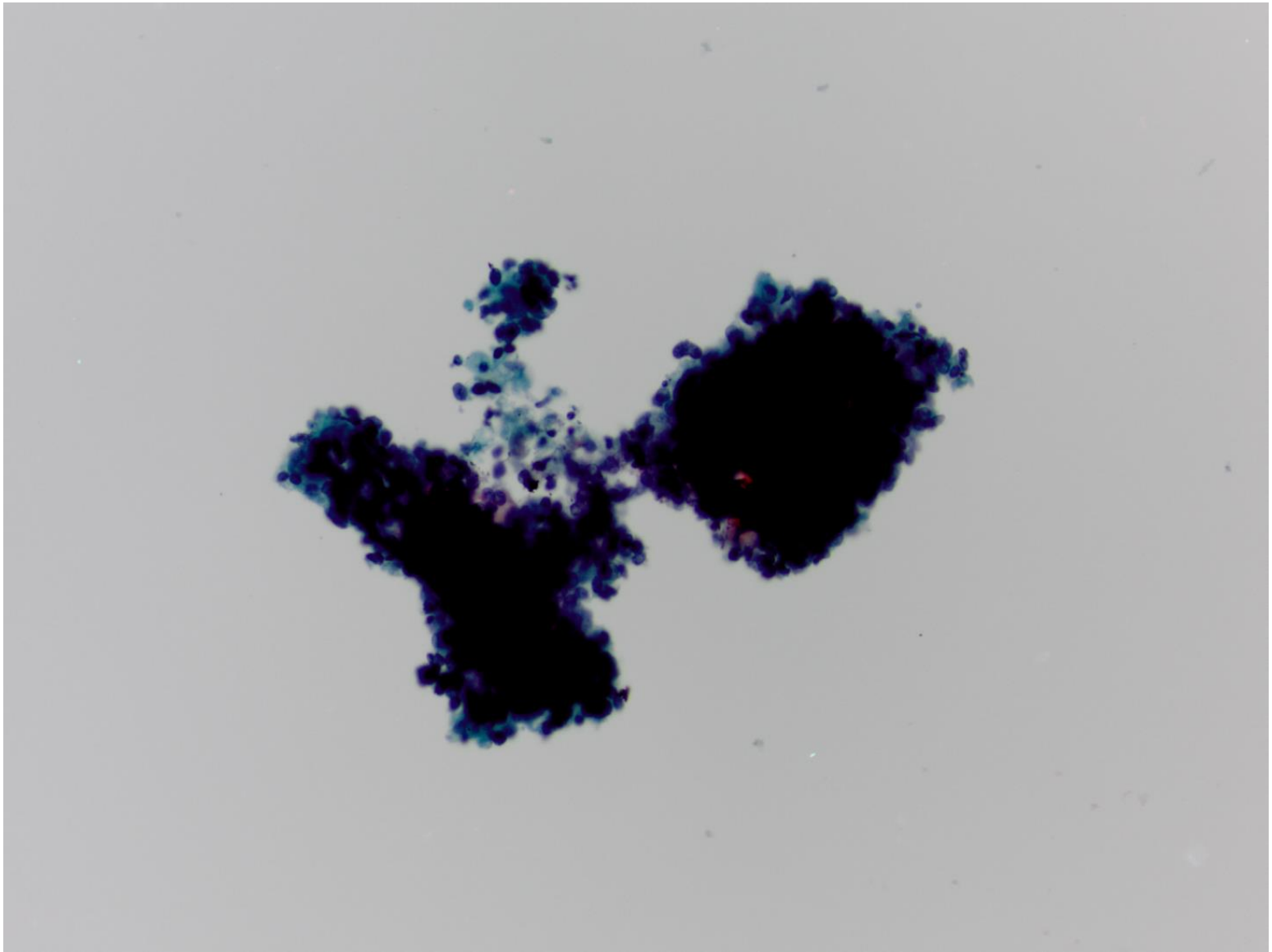

Case 3 - Adrenal Mass Core LBC 2

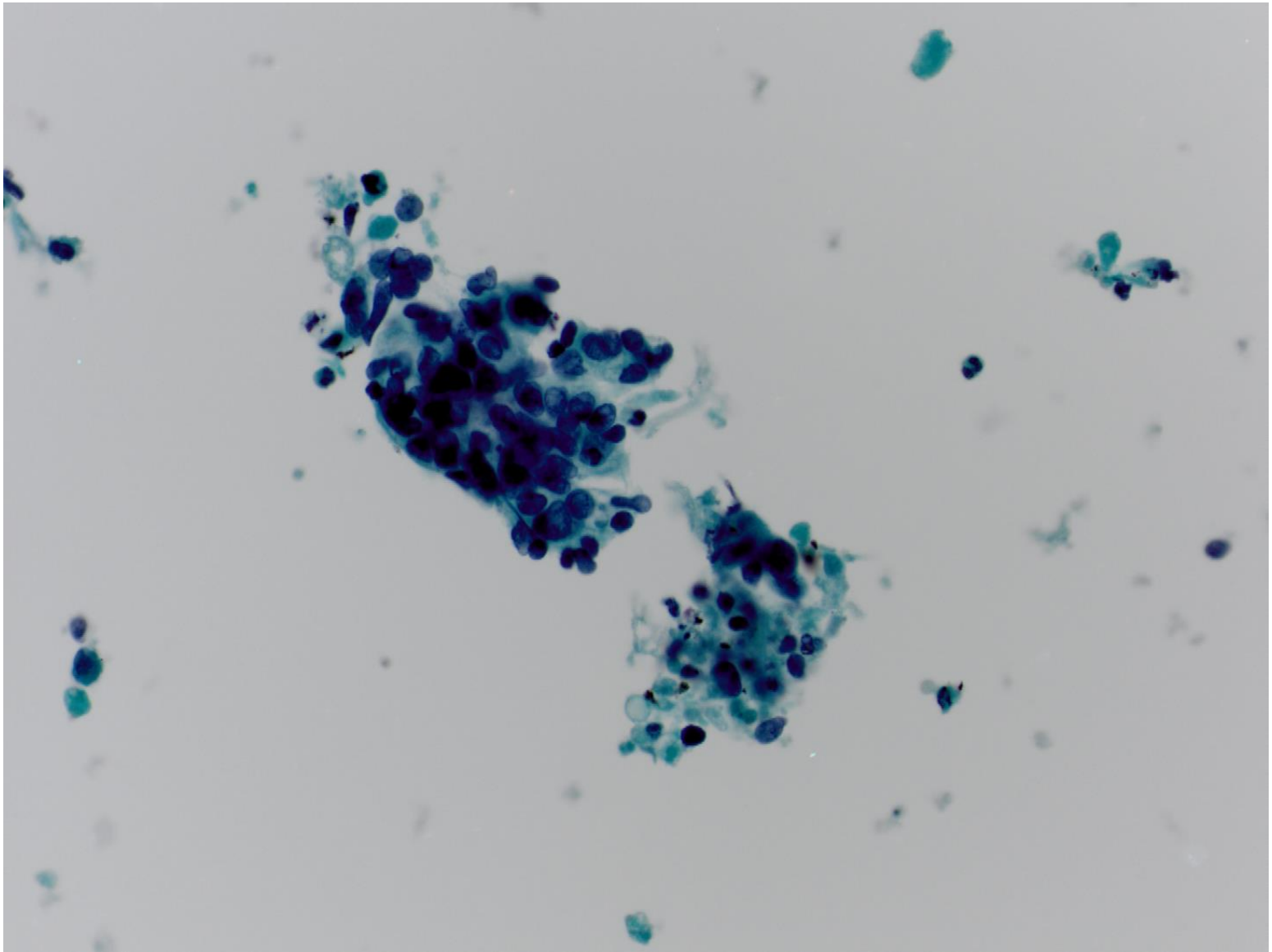

Case 3 - Adrenal Mass Core LBC 3

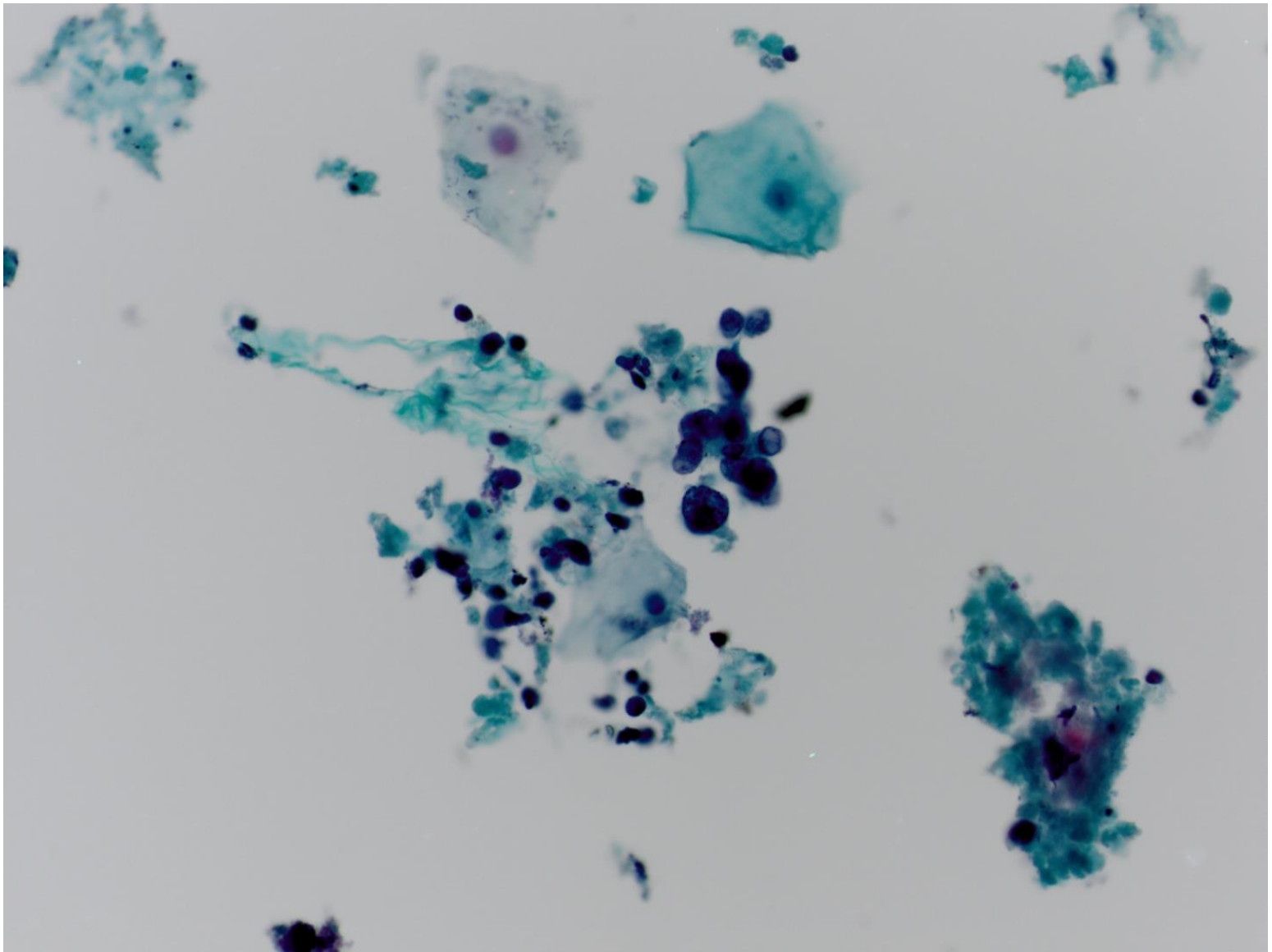

Case 3 - Adrenal Mass Core Rapid MGG

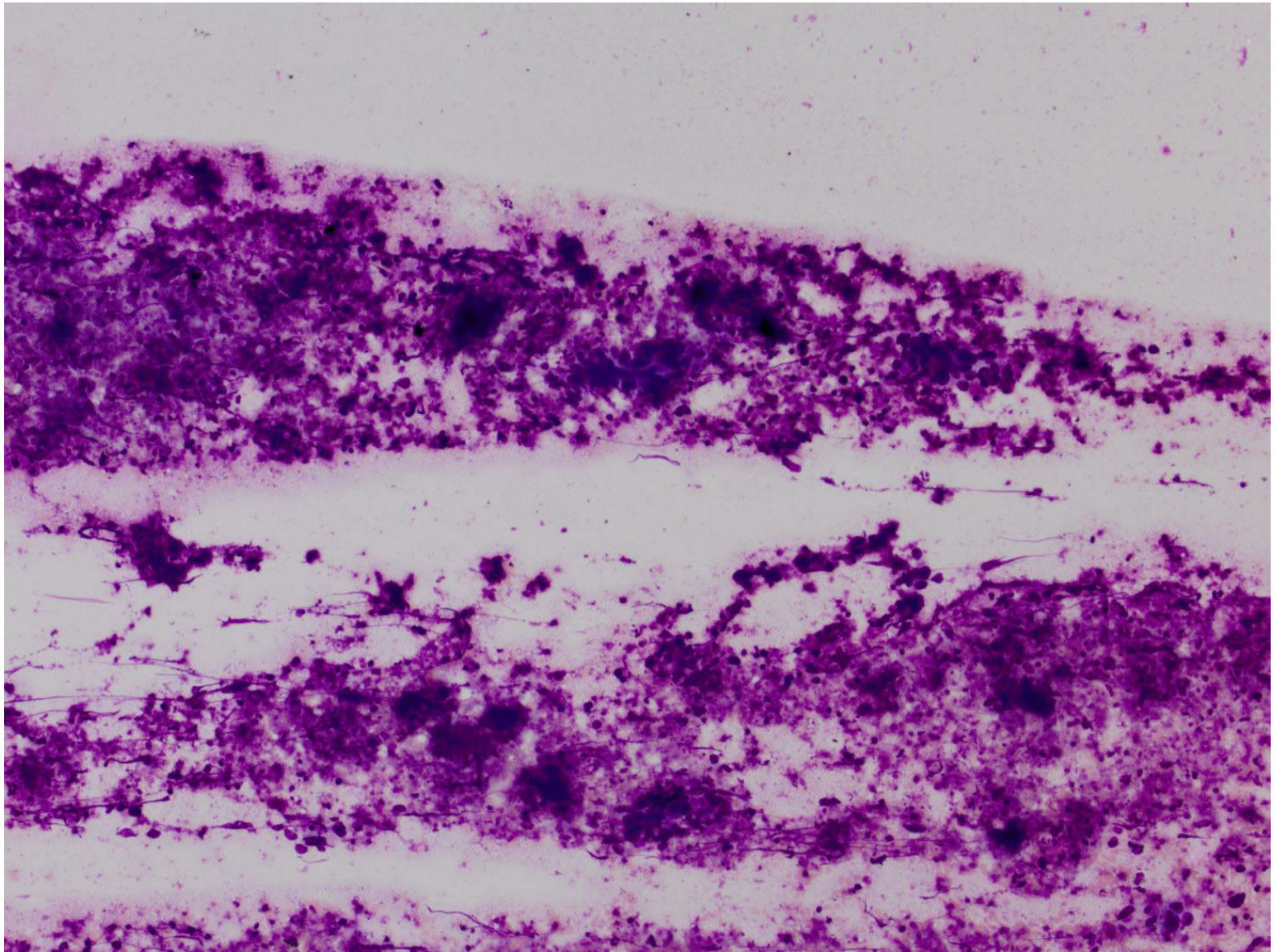

Case 3 - Adrenal Mass Core Rapid MGG 2

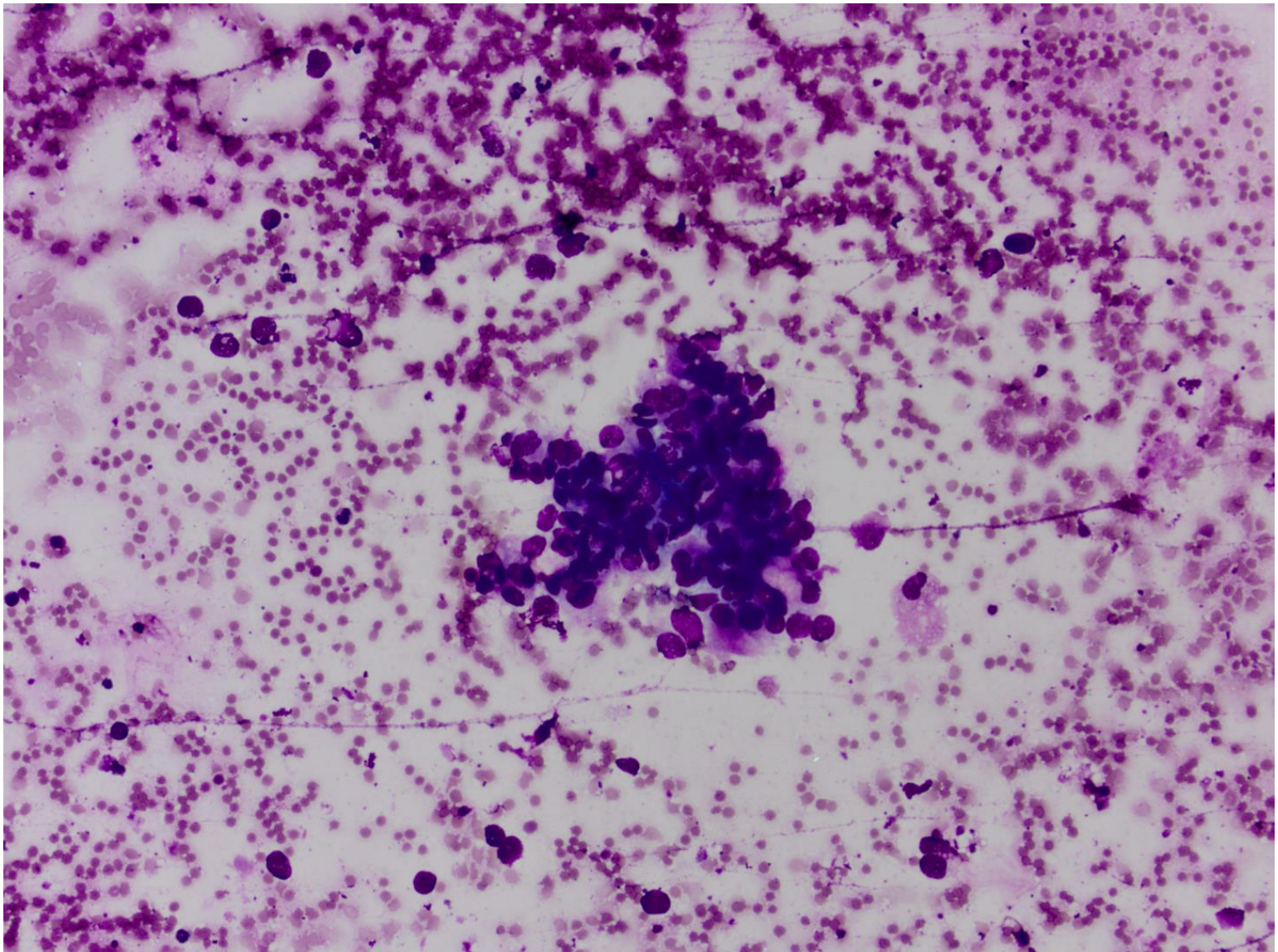

Case 3 - Adrenal Mass Core Rapid MGG 3

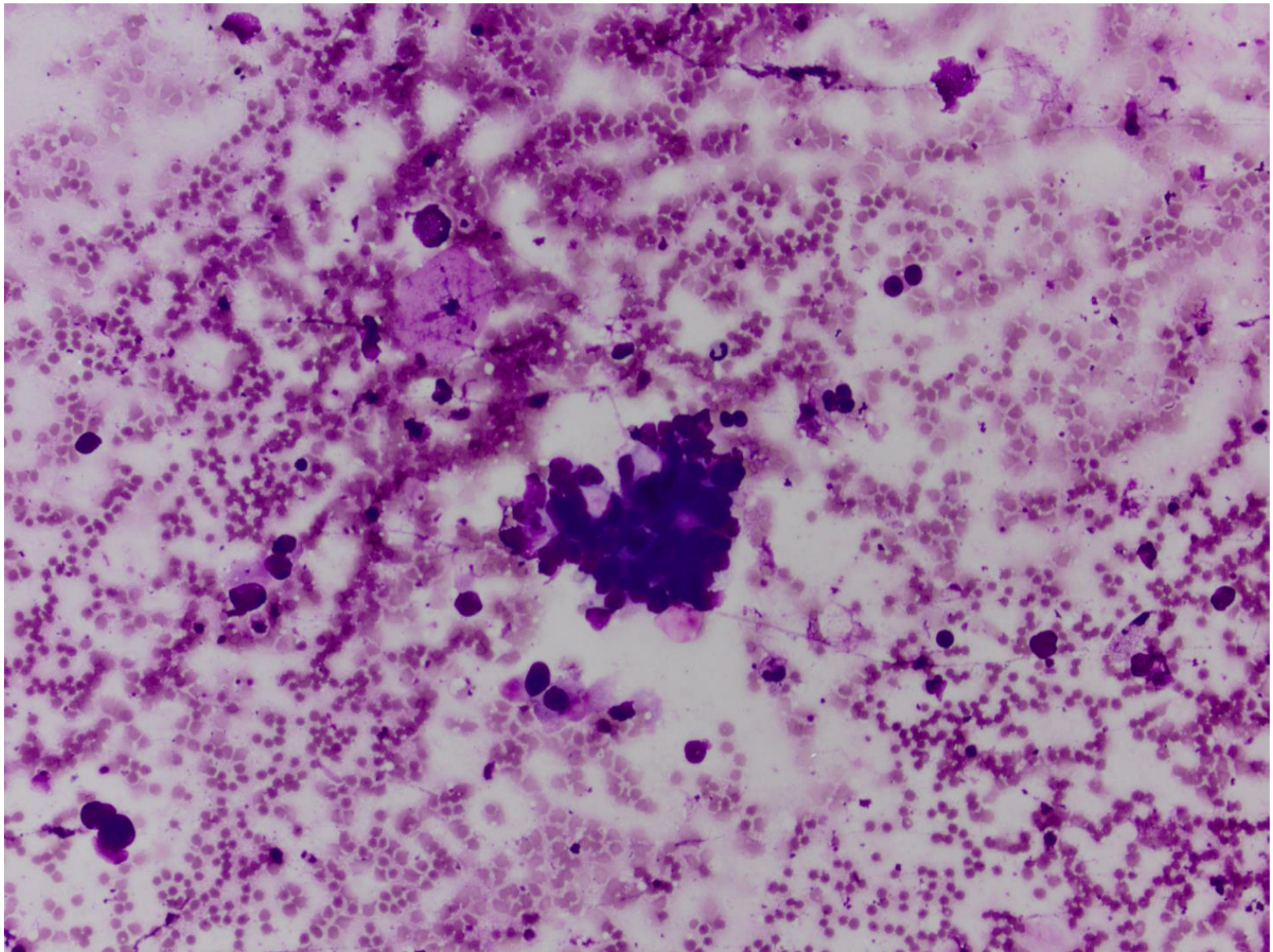

Case 3 - Adrenal Mass Core H&E

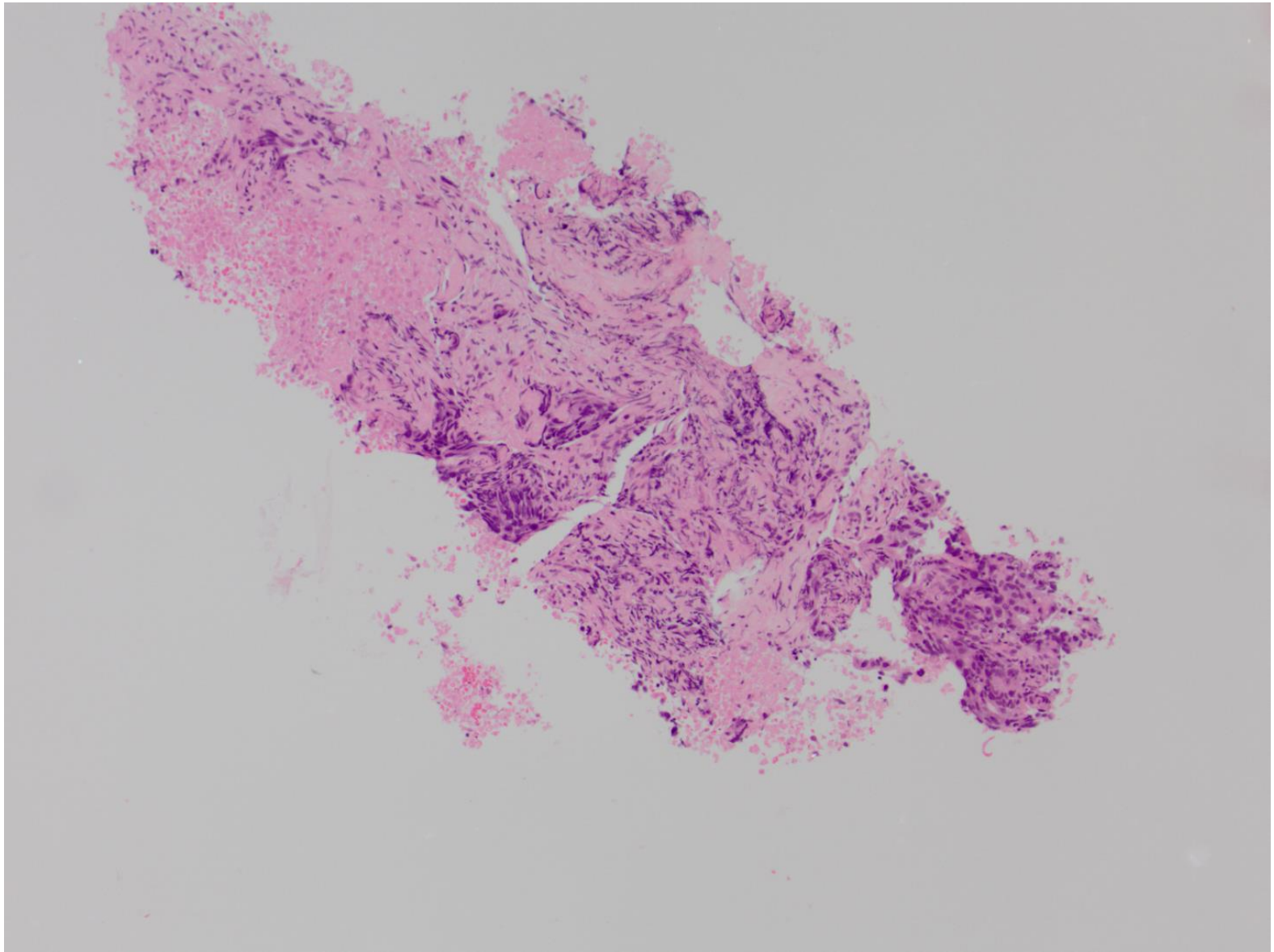

Immunoprofile and Molecular Tests

- CK7 - positive
-
- TTF1, CK5/6, p63 - all negative
-
- Primary origin not clearly established
-
- Immunoprofile would support upper GI or a lung primary origin, despite the lack of TTF1 positivity, which can be seen in a small percentage of primary lung adenocarcinomas.

Case 3 - Adrenal Mass Core CK7

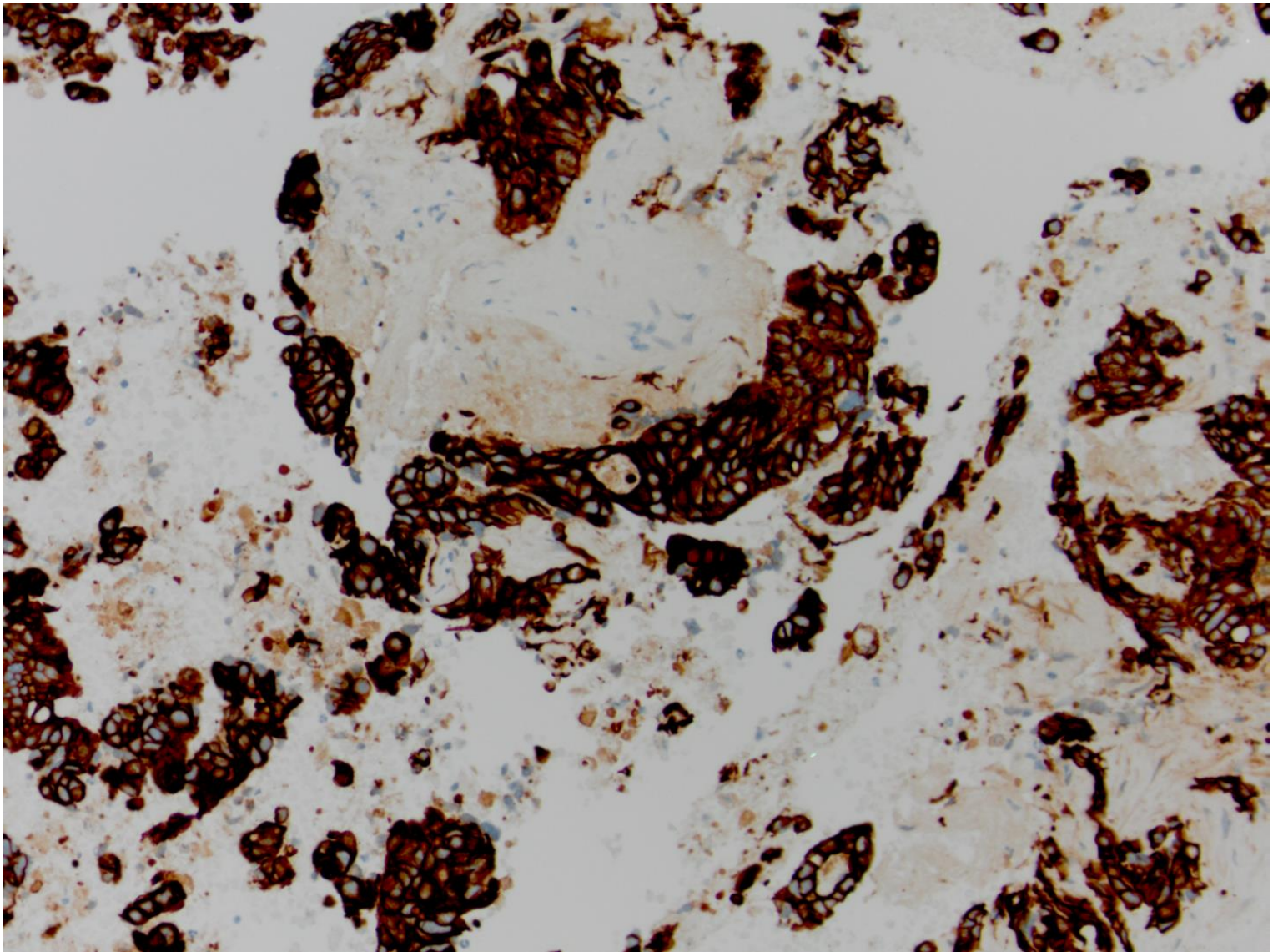

Case 3 - Adrenal Mass Core TTF1

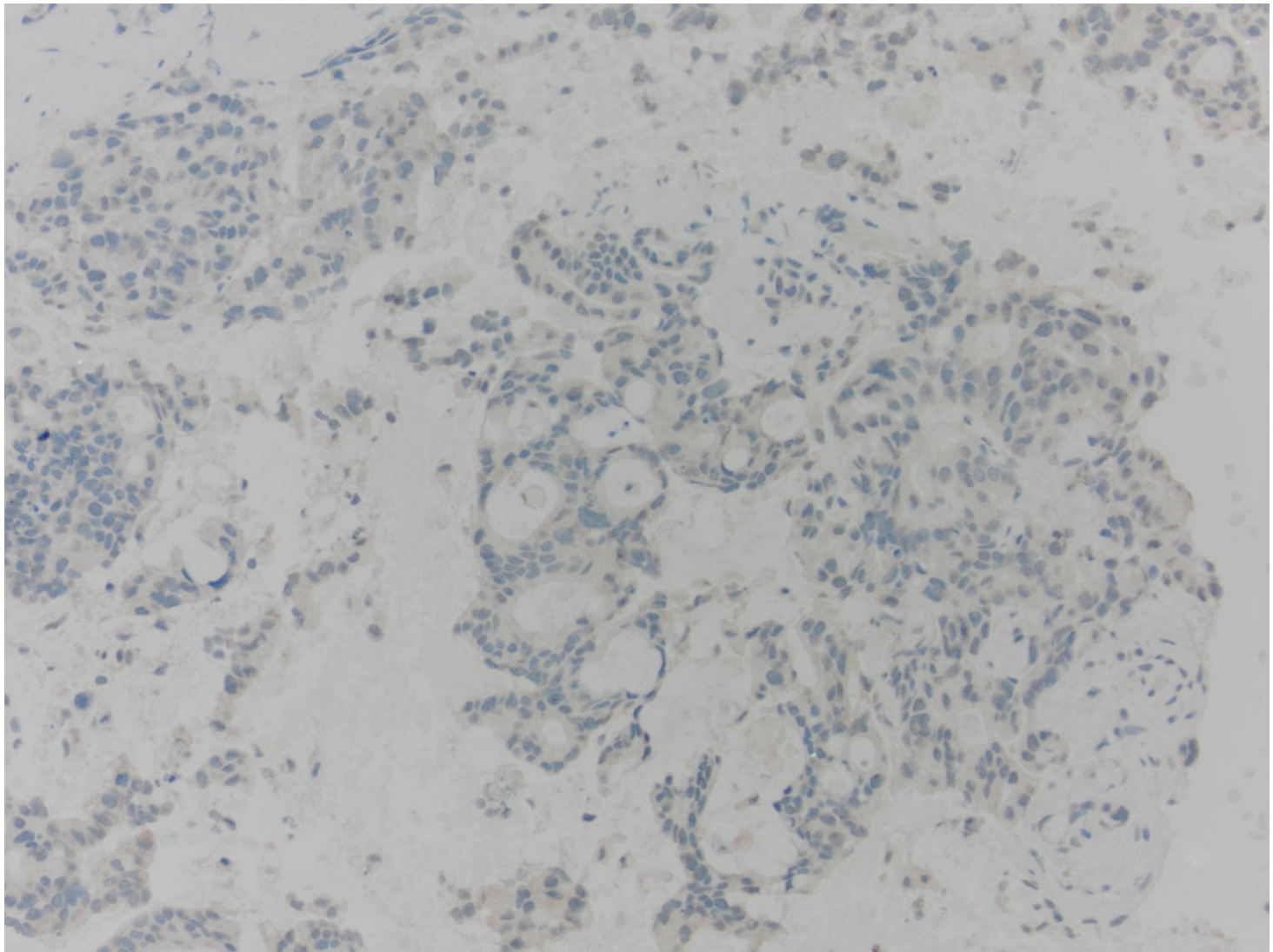

Case 3 - Adrenal Mass Core CK5-6

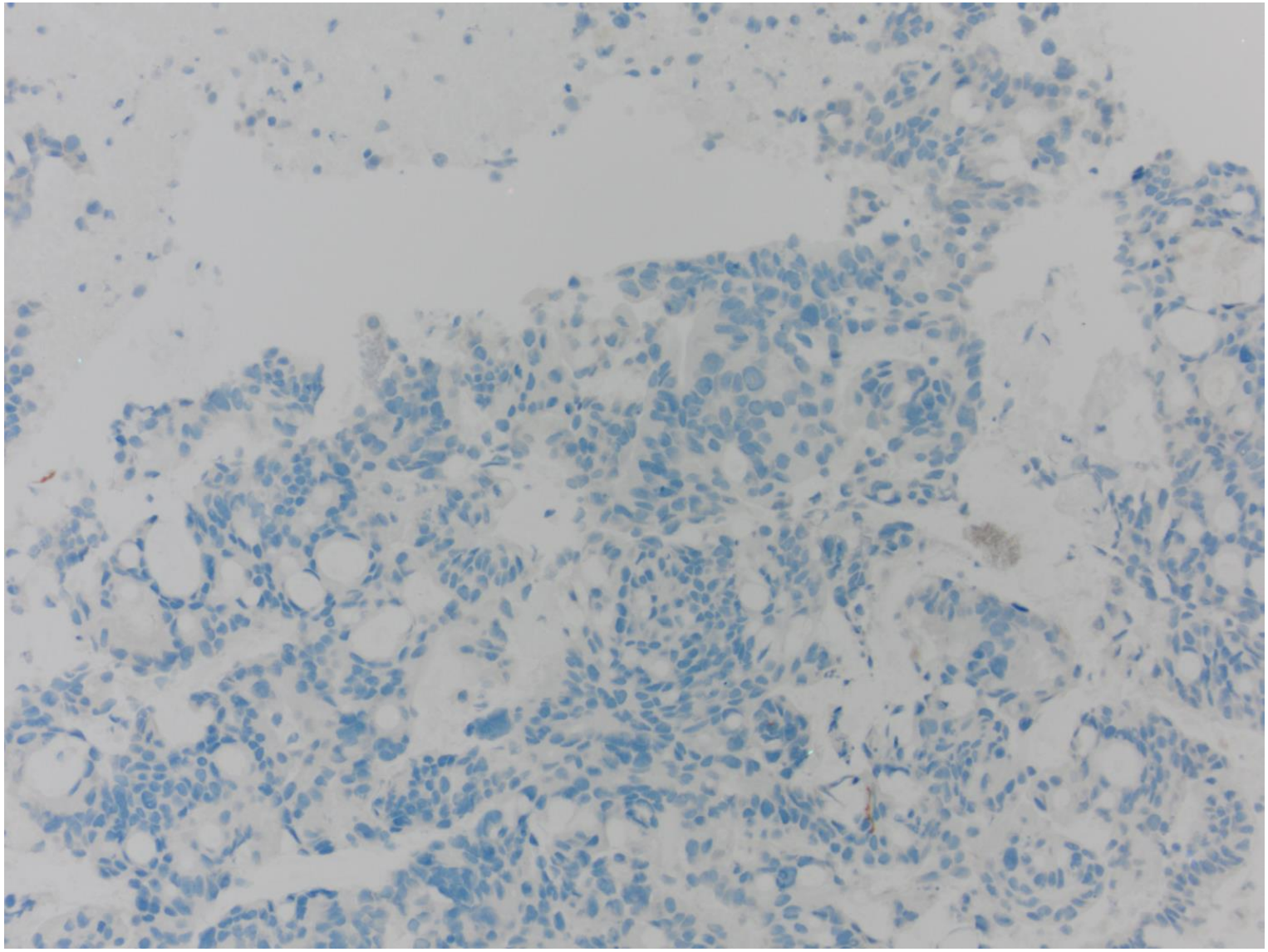

Immunoprofile and Molecular Tests

- ALK is negative
- PDL-1 testing has been carried out at UCL Advanced Diagnostics
- No evidence of an EGFR mutation in this sample

Case 3 outcome

- Histology = adenocarcinoma compatible with lung or upper GI origin
- Immunohistochemistry: compatible with lung
- Progressive disease and died several weeks later

Summary

- EUS
  - Expanding field
  - Ability to access awkward areas
  - Effective service requires multidisciplinary team working
  - On site evaluation useful for assessment of adequacy
  - Trend towards core material/histology